



Patient History:

10 year old 28kg male

Angiography:

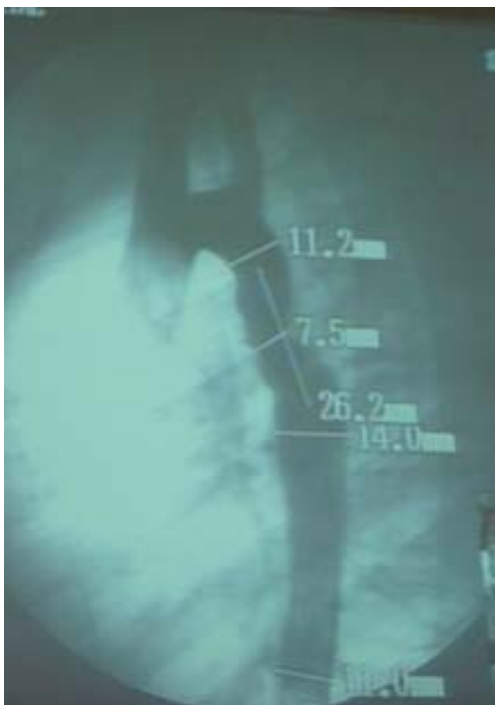
- Coarctation of the aorta measuring 7.5mm at the tightest stricture with a mean pressure gradient of 33mmHg
- Proximal healthy aorta measuring 11.2mm
- Distal post stenotic dilation measuring 14.0mm

Procedural Course:

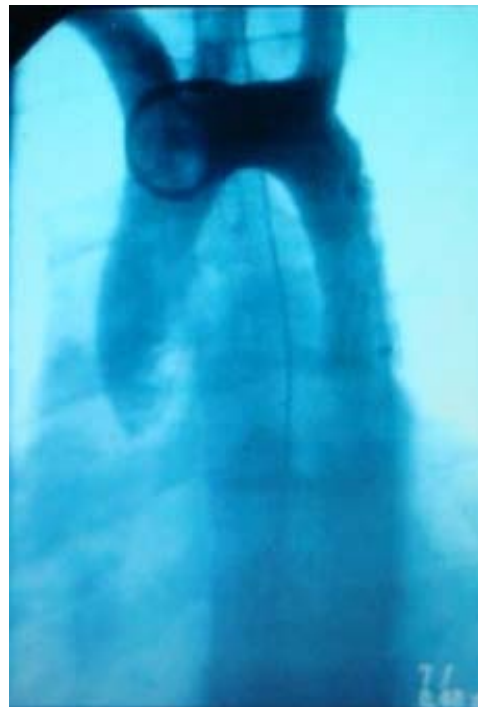- 8Fr x 55cm Cook Raabe sheath placed in the right femoral artery
- LD V12 12mm x 29mm deployed in the aorta
- LD V12 post dilated using a 14mm Bard Atlas™ balloon

Conclusion:

Excellent clinical result. Post stenting pressure gradient was 0mmHg.



Coarctation of the Aorta



Final Result after 12mm x 29mm LD
V12 Deployed