




*Managing
Chest Drainage
Continuing
Education
Program*



ATRIUM

**Chest Drainage
Continuing Education Program**

Chest Drainage Continuing Education Program

■ Introduction

This continuing education activity is designed to provide registered nurses with information about chest drainage. Our goal is for nurses to better understand the physiology and pathophysiology relating to conditions requiring chest drainage. Learning about the safe and effective use of chest drain systems will allow registered nurses to provide high quality care for their patients.

■ Continuing Education Approval

This self-study activity is approved New York State Nurses Association, accredited by the American Nurses Credentialing Center of the American Nurses Association for 1.6 contact hours. This approval is recognized nationwide. However, as with any continuing education activity, the professional registered nurse is responsible for confirming this activity is accepted by individual state boards of nursing and certification boards, as required for licensure or certification renewal.

To receive a certificate verifying participation in this activity and the awarding of contact hours, complete the program online at <http://www.atriummed.com/CE>. You can complete the post-test and evaluation, and on successful completion, print out your certificate immediately.

This activity was revised in July 2008 and approved on August 5, 2008. No continuing education credit will be offered after August 4, 2010.


■ Recommended Instructions for Use

1. Review the stated learning objectives on page ii and compare them with your own learning needs. If you require additional information or clarification after completing this activity, you may refer to the suggested readings beginning on page 38, consult with an expert nurse, contact Atrium Medical Corporation at 1-800-5 ATRIUM (528-7486) or your local Atrium sales representative.
2. Preview this self-study monograph. Note the headings, illustrations, and the highlighted information.
3. Read the self-study monograph. Highlight areas of special interest to you, or those you want to follow up on. Take notes as you wish. Use the glossary to define terms that may be unfamiliar to you. Glossary terms are in bold type in the text the first time they are mentioned.
4. After reading the monograph, complete the post-test questions online as noted above to receive your certificate.

■ For Additional Information: Clinical Update

Atrium has provided the Clinical Update newsletter as an educational service since 1997. All back issues are available online at the Atrium Web site:

<http://www.atriummed.com/clinicalupdate>

Throughout this monograph, when additional information is available in Clinical Update, this symbol  will be followed by the issue in which the topic was addressed. For example:

 See Clinical Update: Mar 2001

Throughout this monograph, the terms physician and surgeon are used for convenience. Depending on the practice setting, this role may be filled by an Advanced Practice Registered Nurse or Physician's Assistant. When describing the fluid-filled chambers of a chest drain, the word water is used for simplicity. Sterile water or sterile saline may be used unless contraindicated by the manufacturer. Nurses are responsible for following the latest patient safety and infection control directives, according to hospital policy and procedure.

■ Learning Objectives

At the completion of this self-study activity, the learner should be able to...

- 1... describe the normal anatomy of the chest.
- 2... explain the changes that occur in the thoracic cavity during breathing.
- 3... identify abnormal conditions requiring the use of chest drainage.
- 4... discuss the features of the traditional three-bottle chest drainage system.
- 5... compare and contrast the traditional three-bottle chest drainage system with the self-contained disposable chest drainage units available today.
- 6... recognize steps in setting up a chest drainage system.
- 7... outline key aspects of caring for a patient requiring chest drainage.
- 8... recognize four signs indicating a chest tube can be removed.
- 9... summarize the use of autotransfusion with chest drain systems.

■ What do you want to learn from this self-study activity?

■ Contributors

This self-paced learning activity was prepared by:

Patricia Carroll, RN,BC, CEN, RRT, MS

Owner, Educational Medical Consultants

Meriden, CT

www.nursesnotebook.com

Ms. Carroll designs educational materials as a consultant to Atrium Medical Corporation. She has no financial interest in the company.

Jeffrey P. McGill

Senior Vice President of Marketing &

Corporate Communications

Atrium Medical Corporation

Hudson, NH

It is provided through an unrestricted educational grant from Atrium Medical Corporation

Table Of Contents

Page

Anatomy Of The Chest	1
The Thorax	1
The Mediastinum	1
The Lungs And Lung Cavities	2
Respiratory Physiology	3
Pathophysiology	4
Pneumothorax	5
Tension Pneumothorax	6
Hemothorax	7
Cardiac Tamponade	8
Chest Drainage Systems	10
Chest Tubes	11
Patient Tubing	12
Reusable Chest Drainage Systems	13
One-Bottle Chest Drainage System	13
Two-Bottle Chest Drainage System	14
Three-Bottle Chest Drainage System	14
Suction Control Bottle	15
Drawbacks Of The Three-Bottle System	15
Disposable Chest Drainage Systems	16
Collection Chamber	16
Water Seal Chamber	17
Dry Seal Chest Drains	17
Suction Control Chamber	18
Double Collection Chest Drains	19
Infant Chest Drainage Systems	19
Closed Wound Reservoirs	19
Setting Up A Chest Drain	20
Thoracostomy	20
Steps For Chest Tube Insertion and Drain Setup	21
Caring For Patients Requiring Chest Drainage	23
Respirations	23
Knowledge Level	23
Pain Control	23
Vital Signs	23
Patient Position / Movement	23
Chest Tube Site / Dressing	25
Tubing	25
Drainage Fluid	26
Water Seal	26
Suction	27

Disconnecting The Chest Drainage Unit29
Removing The Chest Tube30
Autotransfusion31
The Future is Now: Mobile Chest Drains32
Summary34
Glossary35
Suggested Readings38
Classic References45
Suggested Readings Regarding Chest Tube Stripping46

Anatomy Of The Chest

■ The Thorax

The **thorax** lies between the neck and the abdomen. The walls of the thoracic cavity are made up of the ribs laterally, the **sternum** anteriorly, and the thoracic vertebrae posteriorly. Internal and external **intercostal** muscles cover bony thoracic structures. The dome-shaped, muscular **diaphragm** forms the lower boundary (sometimes called the floor) of the thoracic cavity. See Figure 1 for key anatomical structures of the chest.

The thoracic cavity forms a semi-rigid framework that protects the heart, lungs, great vessels, the thymus gland and parts of the **trachea** and esophagus. In addition, the structure forms an airtight bellows mechanism (which will be described in more detail in the next section), creating a vacuum system that expands the lungs during inspiration.

The thorax is divided into three distinct spaces:

- The centrally located mediastinum
- The right lung cavity
- The left lung cavity

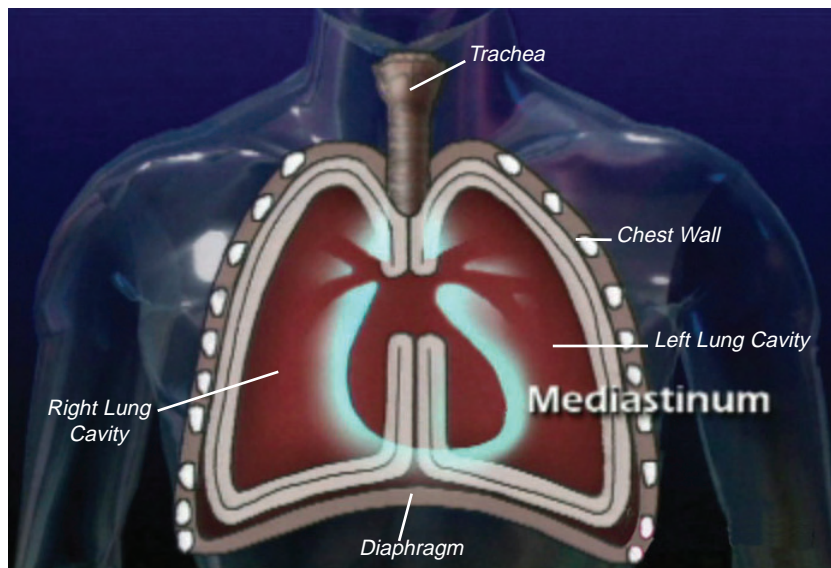


Figure 1. Anatomy Of The Chest

■ The Mediastinum

The **mediastinum** is a flexible partition in the center of the thoracic cavity. The left and right lung (pleural) cavities are lateral to the mediastinum, the sternum is anterior, and the vertebral column is posterior.

The mediastinum contains the heart, covered by the **pericardium**; the thymus gland; parts of the esophagus and trachea; and a network of nerves and blood vessels.

■ The Lungs And Lung Cavities

The cone-shaped, spongy, elastic lungs are suspended from the trachea and fill a substantial portion of the thoracic cavity. The left lung is narrower, longer and smaller than the right (because of the position of the heart toward the left of midline); it is divided into two lobes: the upper and lower lobes. The larger right lung is divided into three lobes: upper, middle and lower.

Air is drawn into the thoracic cavity through the upper airway. The trachea divides into two primary bronchi (one **bronchus** to each lung), which in turn divide many times into smaller and smaller airways that eventually terminate in the **alveoli**, where gas exchange takes place across the alveolar-capillary membrane.

The boundaries of each airtight lung cavity consist of the chest wall, the diaphragm and the mediastinum. This cavity is lined with a membrane called the **parietal pleura**. A similar membrane called the pulmonary or **visceral pleura** covers the surface of each lung.

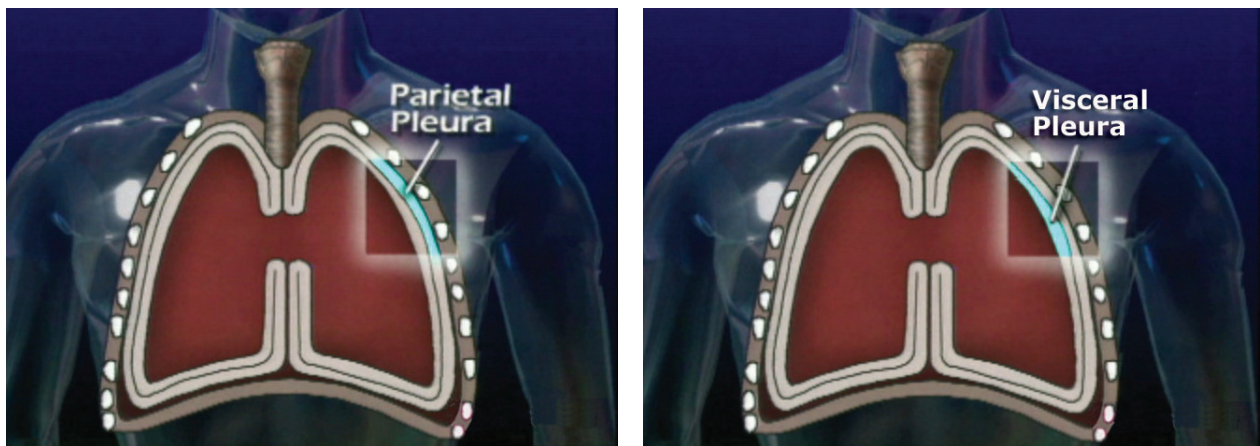


Figure 2. The membrane lining the chest wall (L) and covering the lungs (R)

A thin film of serous lubricating fluid called pleural fluid separates the parietal and visceral pleural surfaces. This fluid allows the moist pleural membranes to adhere to one another while allowing them to slide smoothly as the lung expands and recoils during inhalation and exhalation. The amount of fluid produced in 24 hours is about 0.3mL/kg of body weight or about 25mL.

The lungs have a natural tendency to collapse or recoil. The adherence of the pleurae keeps the lungs pulled up against the inside of the chest wall, counterbalancing the natural recoil. This tendency for the lungs to pull away from the chest wall results in a subatmospheric, or negative, pressure in the tiny space between the pleurae. Normally, this intrapleural pressure is approximately $-8\text{cmH}_2\text{O}$ during inspiration and $-4\text{cmH}_2\text{O}$ during expiration. This negative pressure keeps the lungs expanded and allows them to move in tandem with the rib cage and diaphragm during inspiration.

Respiratory Physiology

Normal breathing consists of:

- Ventilation: the mechanical act of moving air into and out of the lungs
- Respiration: gas exchange across the alveolar-capillary membrane

During normal ventilation, air moves in and out of the thoracic cavity through the trachea by the following process (See Figure 3):

1. During inspiration, the phrenic nerve stimulates the diaphragm to contract, causing it to move downward. At the same time, the external intercostal muscles may also contract, pulling the chest wall out. Both actions increase the size of the thoracic cavity.
2. Because of the adherence of the pleurae, as the thoracic cavity enlarges, the lungs expand as well.
3. As the volume of the lung increases, the pressure within decreases. (This is according to Boyle's gas law, which states there is an inverse relationship between volume and pressure.) This creates a negative intrapulmonary pressure.
4. Air naturally moves from areas of higher pressure to areas of lower pressure. Thus, air will be drawn into the lungs through the trachea when intrapulmonary pressure becomes more negative.
5. During exhalation, the muscles of the diaphragm and intercostals relax. The chest wall moves in, and the lung volume decreases through natural elastic recoil.
6. As lung volume decreases, intrapulmonary pressure rises in relation to atmospheric pressure (again, by Boyle's gas law).
7. Air now flows from the lung out through the trachea.
8. The cycle then repeats approximately 25,920 times a day.

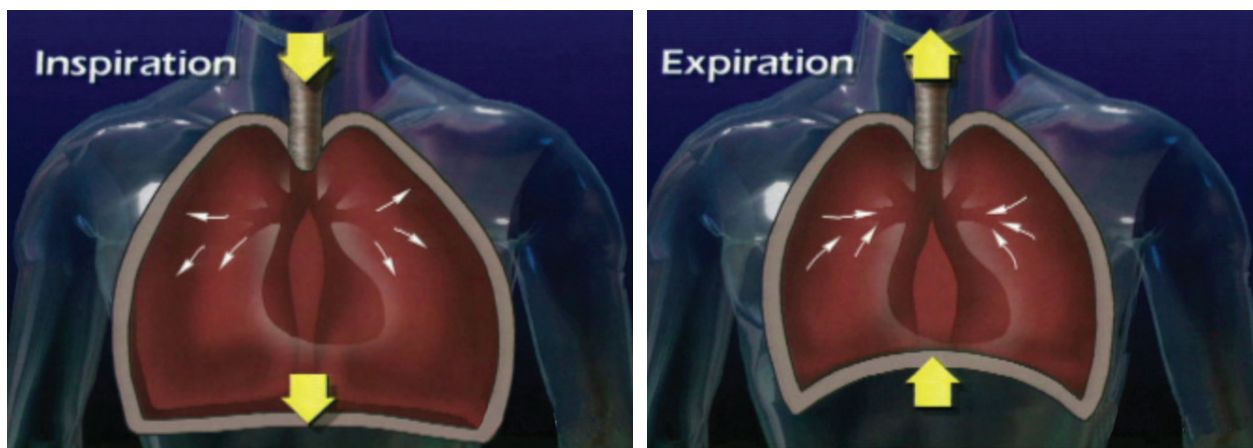


Figure 3. The mechanics of breathing

Pathophysiology

If air, fluid, or blood enters the tiny space between the parietal and the visceral pleurae, the negative pressure that keeps the pleurae adherent and holds the lungs against the chest wall will be disrupted. The lung's natural tendency to recoil will take over and the lung will collapse. When this occurs, the lung cannot fully expand during inspiration. (See Figure 4). Depending on the patient's underlying pulmonary condition and the degree of disruption in the pleural space, the patient may experience minimal symptoms or significant shortness of breath. In addition, the parietal pleurae are highly innervated with sensory nerves, so any change in the pleural space may be very painful as well. Pleuritic pain is characterized by a sharp, stabbing pain during inspiration as the pleurae move. Patients will involuntarily reduce tidal volume while increasing respiratory rate to maintain ventilation while limiting the movement of the pleurae to reduce pain.

Typically, air or fluid must be removed from the pleural space before the lung can fully re-expand and normal breathing can resume. In situations in which the air or fluid accumulation is very small, the patient may be monitored carefully while the body naturally absorbs the air or fluid.

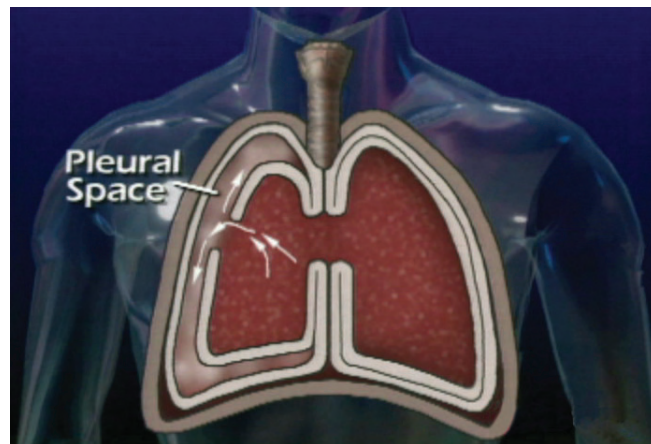
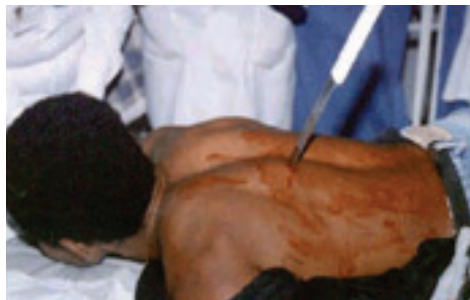

Figure 4. Air in the pleural space

Two common clinical conditions require pleural drainage:

- Rupture of the surface of the lung (such as a bleb) or tracheobronchial tree, allowing air and possibly serous or **serosanguineous** fluid into the pleural space while the chest wall remains intact
- External penetration of the chest wall resulting from surgical intervention or trauma (such as a gunshot wound or stabbing), allowing air and blood or serosanguineous fluid from damaged tissues into the pleural space (See Figure 5).



Since trauma typically injures both the chest wall and the lung surface, air can enter the pleural space from the atmosphere (through the opening in the chest wall) or the lung. Bleeding may come from the chest wall or the lung itself.

Figure 5. Stab wound to left hemithorax
courtesy trauma.org

■ Pneumothorax

Whenever the chest wall is opened or the lung is penetrated, either surgically or through traumatic or iatrogenic injury (such as placement of a central venous catheter), air enters the pleural space and the negative pressure between the pleurae vanishes, allowing the lung to collapse. This condition of air in the pleural space is called a **pneumothorax**.

If air enters the pleural space through traumatic penetration of the chest wall by a gunshot wound, stabbing, impalement or other similar trauma, leaving the pleural space open to the atmosphere, the condition is called an **open pneumothorax**, or a "sucking chest wound" (See Figure 6). Air can freely move in and out of the pleural space through the hole in the chest wall. As long as the hole in the chest is significantly smaller than the trachea, the patient may be able to tolerate the open pneumothorax for some time; however, rapid, definitive treatment is certainly the goal.

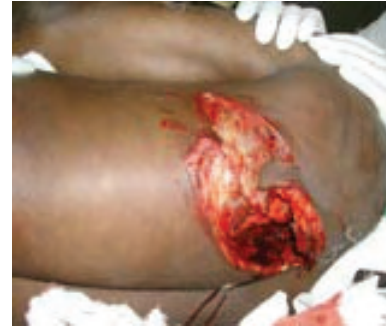

Figure 6. Open chest wound left upper posterior chest, open pneumothorax
courtesy trauma.org

If air enters the pleural space through rupture of the lung and visceral pleura (such as barotrauma from mechanical ventilation), but the chest wall remains intact, the condition is called a **closed pneumothorax**. In this case, air can enter the pleural space but it cannot escape as easily as in an open pneumothorax (See Figure 7).

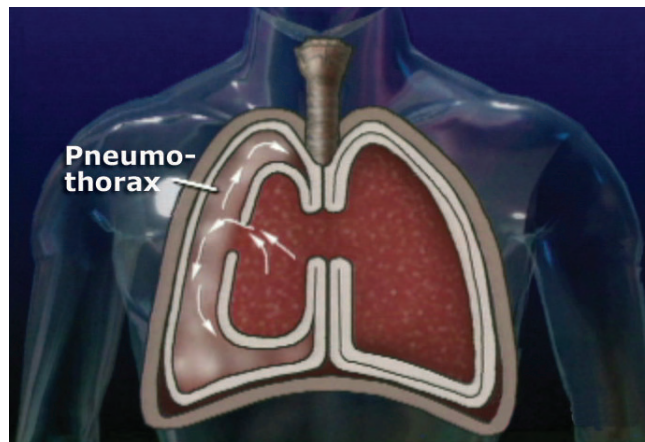


Figure 7. Closed pneumothorax

Occasionally, a patient may experience a pneumothorax for no obvious reason. This condition is called a **spontaneous pneumothorax**. One theory is that this condition is more common in young men who have had a growth spurt during which skeletal growth exceeds lung growth. This discrepancy results in great tension on the pleurae at the apex of the lung, where rupture is most likely to occur. A spontaneous pneumothorax can also occur when an emphysematous bleb on the lung surface ruptures. These patients will develop shortness of breath and pleuritic chest pain. If the volume of air in the pleural space is small, the patient may be monitored carefully while the body reabsorbs the air.

Guidelines from the American College of Chest Physicians classify spontaneous pneumothorax into two categories: primary spontaneous pneumothorax, in which there is no evidence of underlying lung disease, and secondary spontaneous pneumothorax, in which there is evidence of underlying lung disease such as chronic obstructive pulmonary disease, lung infections that weaken the lung tissue, and lung cancer. ■ See Clinical Update: Jun 2001 (Part 1), Sept 2001 (Part 2)

■ Tension Pneumothorax

When air continues to leak into the pleural space with no means of escape there will be a rapid build-up of pressure in the pleural space. This serious condition is called **tension pneumothorax**. The increasing intrapleural pressure becomes positive, eliminating the normal negative intrapleural pressure.

If pressure becomes high enough, the lung can completely collapse and the pressure can then be transmitted to the mediastinum. The mediastinum can be pushed away from the affected side; this shift can compress the great vessels and the heart itself. If this occurs, venous return to the heart will be reduced, resulting in a significantly decreased cardiac output. Blood pressure will drop precipitously. This **mediastinal shift** is a life-threatening situation; prompt recognition and treatment are essential to avert cardiovascular collapse and death. (See Figure 8).

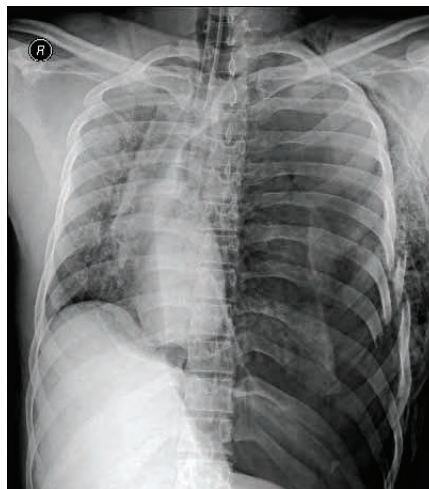


Figure 8. Chest radiograph of left tension pneumothorax. Note how the pressure in the chest pushed the diaphragm down and moves the mediastinum into the right side of the chest. *Courtesy trauma.org*

Patients receiving positive pressure ventilation (either from a ventilator or manual resuscitation bag) are at particular risk for complications from tension pneumothorax compared with spontaneously breathing patients because air is pushed into the chest under pressure with each breath. Patients with artificial airways are also unable to talk, making it more difficult for them to alert the nurse to changes in their breathing and pleuritic chest pain.

Because a tension pneumothorax can severely compromise both breathing and circulation, careful nursing assessment is essential to detect tension pneumothorax promptly so definitive treatment can be carried out. Signs and symptoms include:

- Increased respiratory rate and effort
- **Dyspnea**
- Pleuritic chest pain (if the patient is able to communicate)
- Decreased movement of the affected side of the chest (See Figure 9)
- Decreased breath sounds on auscultation of the affected side
- Falling blood pressure
- Rising pulse

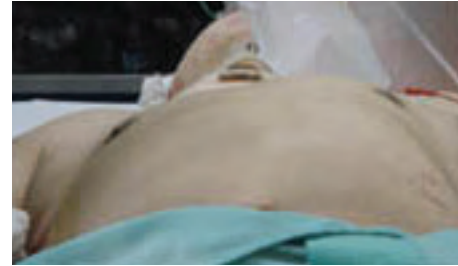

Figure 9. Left side of chest is fixed at full inspiration, characteristic of tension pneumothorax. *Courtesy trauma.org*

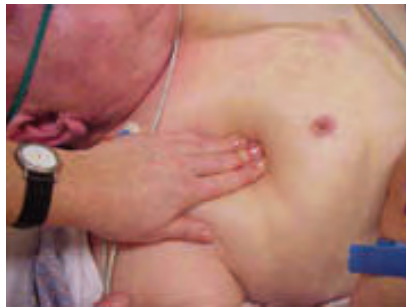

Figure 10. Palpating chest with subcutaneous emphysema. *courtesy trauma.org*

Textbooks classically describe breath sounds as being absent, which leads many nurses to expect that they will hear nothing on the affected side. In reality, sounds from the unaffected side will be transmitted to the side of the chest with the pneumothorax. Thus, breath sounds will be diminished or distant, not absent. Also look for tracheal deviation away from the affected side (however, an artificial airway will make this harder to identify); cool, mottled skin; and **subcutaneous emphysema**, a feeling of crackling on palpation of the chest, indicating air has entered the subcutaneous tissues (See Figure 10). If the patient is receiving volume-controlled, positive-pressure ventilation, the **manometer** on the ventilator will show higher inspiratory pressures and will be less likely to return to zero (or baseline, if PEEP is used). If the patient is being ventilated with a manual resuscitation bag, the bag will become harder and harder to squeeze to deliver a breath.

■ Hemothorax

After thoracic surgery or certain chest injuries, blood may collect in the pleural space. This condition is called a **hemothorax**. A combination of blood and air is called a **hemopneumothorax**. These conditions typically occur after there has been an opening in the chest wall, either during surgery or from a penetrating injury. However, in some cases, blood can accumulate in the pleural space after blunt chest trauma when, for example, sharp ends of fractured ribs lacerate lung tissue (pneumothorax) and blood vessels (hemothorax).

Like pneumothorax, hemothorax disrupts the normal negative intrapleural pressure. This allows normal lung recoil to occur, resulting in some degree of lung collapse, depending on how much blood is in the pleural space. Once the lung has collapsed, it does not reexpand until the blood is evacuated from the pleural space (See Figure 11).

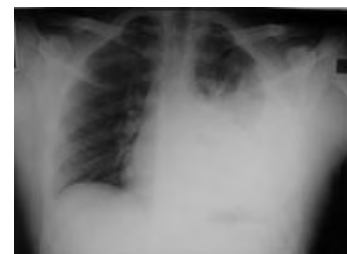

Figure 11. Left hemothorax. Note the compression of the left lung.

courtesy trauma.org

Another collection of fluid in the pleural space occurs when there is a disruption of the normal balance between the amount of pleural fluid produced and the amount of fluid absorbed. This is called a **pleural effusion**. This condition is commonly seen in patients with lung and breast cancer. ■ See Clinical Update: Dec 2002 and Dec. 2005.

Empyema (pyothorax) is an accumulation of pus in the pleural space, caused by pneumonia, lung abscess or contamination of the pleural cavity. **Chylothorax** is the accumulation of lymphatic fluid in the pleural space.

Like pneumothorax and hemothorax, these collections of material in the pleural space disrupt the normal negative intrapleural pressure and interfere with breathing, but none of these fluid collections is likely to result in an accumulation of positive pressure that could threaten the patient the way a tension pneumothorax does (See Figure 12). Without continuous transfusion, a patient would likely **exsanguinate** before enough blood would collect in the pleural space to affect the mediastinum.

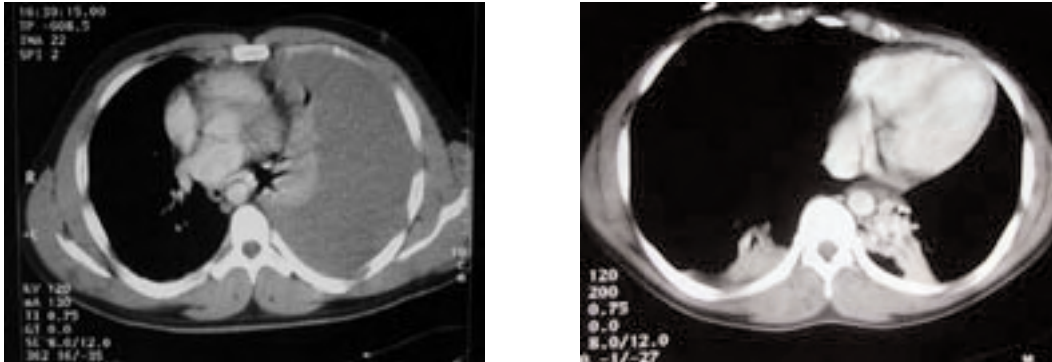


Figure 12. The CT image on the left is a hemothorax. Note the light color of the right hemithorax where the blood is collected and the lack of mediastinal shift. The CT image on the right is a tension pneumothorax. Note the blackness of the left hemithorax where air is trapped under pressure and the shift of the mediastinum to the right side.

courtesy trauma.org

However, blood, fluid, pus, or lymphatic drainage that has accumulated in the pleural space will still cause an inflammatory response and prevent the lung from full expansion during inspiration and should be removed, particularly if the patient is symptomatic with shortness of breath and/or pleuritic chest pain. Generally, if the costophrenic angle is obscured on an upright chest radiograph, the collection is large enough to be drained.

■ Cardiac Tamponade

Following cardiac surgery or chest trauma, blood can pool in the mediastinal cavity. Blood can collect between the pericardium and the heart, externally compressing the heart in a condition called **cardiac tamponade**. Cardiac tamponade, like tension pneumothorax, is life-threatening if not identified and treated promptly because it reduces the heart's ability to accept venous return, resulting in significantly decreased cardiac output. Emergency treatment is needle pericardiocentesis. (See Figure 13).

An accumulation of blood in the pericardium also provides a medium for bacterial growth, potentially leading to postoperative infection.

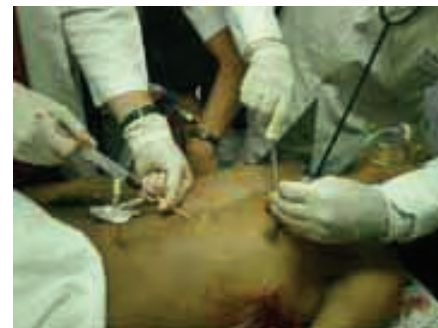

Figure 13. Emergency management of cardiac tamponade is a needle pericardiocentesis, usually followed by chest tube placement.

courtesy trauma.org

To reduce the risk of blood accumulation in the mediastinum, at least one, and more commonly, two chest tubes are used postoperatively to drain the mediastinal cavity to allow blood to leave the chest (See Figure 14).

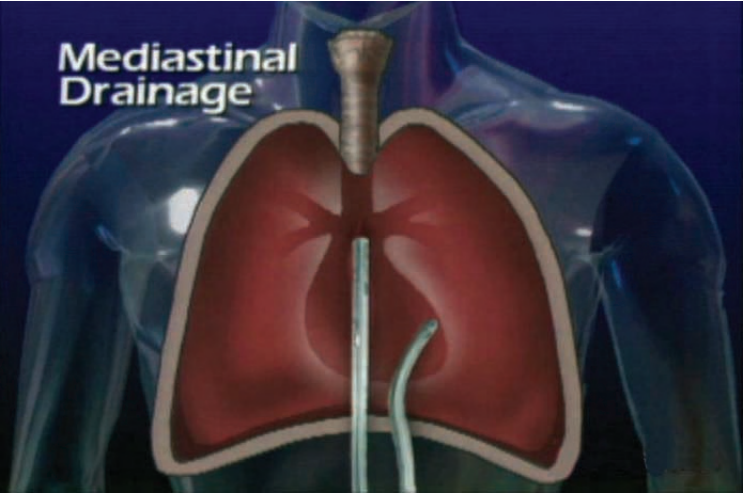


Figure 14. Mediastinal chest tube placement
courtesy trauma.org

Chest Drainage Systems

Most patients can tolerate a small amount of air or fluid in the **pleural space**, particularly if they do not have lung disease. If less than ten percent of the pleural space is occupied by air or fluid, the patient will typically have few respiratory symptoms and the body can usually reabsorb it without external drainage.

In some cases, needle drainage will be performed to vent air from the pleural space or to allow drainage of fluid (typically pleural effusion) from the chest. Other situations will need chest tube drainage. The decision to place a chest tube is based on the patient's underlying pulmonary condition as well as the amount of air or fluid in the pleural space.

The goals of chest tube drainage are to:

- Remove the fluid and/or air as quickly as possible
- Prevent drained air and/or fluid from re-entering the chest cavity
- Re-expand the lungs and restore normal negative intrapleural pressure

A chest tube is typically connected to a chest drain that collects drainage from the pleural space and allows the lung to re-expand. The drain must be designed so that it prevents air or fluid drainage from being pulled back into the chest during inspiration or when negative pressure is restored in the intrapleural space.

The same type of drain is used to collect blood from the mediastinum to reduce the risk of cardiac tamponade following cardiac surgery or chest trauma. However, during mediastinal drainage, negative pressure within the chest is not as significant a factor as it is during pleural drainage.

All chest drainage systems have some common components:

- A chest tube inserted into the pleural cavity or mediastinal cavity to allow air and/or fluid to leave the chest
- A six-foot length of flexible patient tubing that connects the chest tube to the chest drain system
- A drainage system that usually is made up of three compartments: (1) a collection chamber that collects fluid drainage and allows measurement of drainage volume, (2) a one-way water seal chamber or mechanical valve that lets air leave the chest and prevents outside air from getting in, (3) a suction control chamber or mechanical valve that limits the amount of negative pressure that is transmitted to the chest; this feature allows the safe use of suction to facilitate quicker evacuation of air and/or fluid.

Early chest drainage systems were made up of a set of one, two or three glass or plastic bottles. Sixteen pieces and 17 connections were required to set up a three-bottle system properly. Today, most chest drain systems are self-contained units made of molded plastic. The principles are the same regardless of the type of system used.

■ Chest Tubes

▣ See Clinical Update: Sep 1998

A chest tube (sometimes called a thoracic catheter) is generally about 20 inches long, with four to six eyelets that act as drainage holes on the patient (distal) end and an opening for connection to the chest drainage system on the proximal end, outside the body. A radiopaque line is added to the length of the tube so it can be seen more easily on a chest radiograph. Most manufacturers include a break in this radiopaque line to indicate the location of the eyelet closest to the skin, so that on the radiograph, it will be easy to determine the position of the most proximal opening so the tube can be repositioned if it is not fully inside the chest (See figure 15).

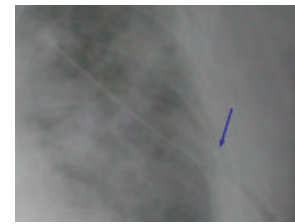

Figure 15. Chest tube eyelet, indicated by blue arrow, outside the pleural space.

courtesy trauma.org

There are two basic types of chest tubes:

- *Thoracotomy chest tube*, a flexible straight or right-angle tube designed for insertion through a small incision in the chest, typically after a surgical procedure. Although some doctors prefer silicone, most chest tubes are made of transparent medical-grade polyvinyl chloride (PVC). Right angle catheters are used most often for mediastinal drainage.
- *Trocar chest tube*, in which the chest tube is packaged with a removable, pointed and rigid stylet. This stylet allows the chest tube to be placed in the chest through a puncture made by the trocar — the physician uses considerable force to push the stylet and chest tube through the chest wall and soft tissue and on into the pleural space. The trocar is then removed, leaving the chest tube in place. This technique is more commonly used in emergency rooms and other areas outside the operating room, in which chest tubes may need to be placed quickly in non-surgical patients. These chest tubes may have only two or three eyelets for drainage. Because of the force needed to insert trochar chest tubes, they present a higher risk for lung injury during insertion than thoracostomy chest tubes.

The diameter of the chest tube selected depends on the size of the patient, the type of drainage (air and/or fluid), and the expected duration of drainage. Typical chest tube diameters are:

- 8 to 12 French Infants and young children
- 16 to 20 French Children and young adults
- 24 to 32 French Most adults
- 36 to 40 French Large adults

With the advent of minimally invasive cardiothoracic surgical techniques, smaller chest tubes are more commonplace to reduce the amount of tissue trauma and speed postoperative recovery.

The Food and Drug Administration (FDA) has approved closed wound drains for postoperative drainage in cardiothoracic surgical patients. The wound drain is attached to a reservoir bulb for drainage — the same type of reservoir bulb used for abdominal wounds, for example — and not connected to a chest drainage device.

A traditional chest tube is a hollow catheter with a single lumen. One type of wound drain has a configuration that changes three times from the patient tip to the proximal end that attaches to the reservoir bulb. The distal end has a multi-lumen, four-channel design. If you look at the lumen at the distal tip of the tube, you'll see a "t" — a PVC core divides the catheter into four separate sections for drainage. (See Figure 16).




Figure 16. Compare wound drain (L) with chest tube (R).

Instead of eyelets found on a traditional chest tube, slits along the wound drain allow fluid into the sections for drainage. In the middle part of the tube, the PVC "t" remains, but the outside of the tube is closed. This section provides the change-over from the open multi-lumen catheter to the third part of the tube that connects to a drainage device — a single-lumen catheter.

Three main variables affect how well blood and fluid leave the chest through a chest tube: the length of the tube, the amount of negative pressure (suction) applied, and the inner diameter of the tube. A tube's ability to evacuate the chest depends on the smallest or most restrictive part of the tube. The middle part of the three-part wound drain is most restrictive, whereas a traditional chest tube's flow rate through a single lumen is constant through the length of the tube. A tube's stated size is determined by its outer diameter, not the flow area inside. When the inner diameter is factored in, the 20 Fr chest tube allows for slightly greater flow than the 24 Fr three-part wound drain, and more than 2.5 times the flow of a 19 Fr wound drain. Thus, a surgeon who might be using a 24 Fr wound drain to achieve better drainage can instead use a smaller chest tube that will disturb less tissue. ■ See Clinical Update: Mar 2004

Chest Drain	Wound Drain
Vents positive pressure	Closed system with no vent
Constant suction level	Variable suction level
Consistent flow rate	Variable flow rate as suction changes
Drainage occurs as long as drain is below the chest	Drainage stops if reservoir fills (100cc) regardless of drain position
Will work even if clinician does not actively maintain drain	Clinician-dependent for proper use
Can be used for all cardiothoracic patients	Cannot be used if patient has an air leak
Remains a closed system throughout use	Must be opened periodically to discard drainage

Table 1. Characteristics of Chest Drains and Wound Drains

■ Patient Tubing

A six-foot tube connects the chest tube to the collection chamber of the chest drainage system. The length of this tubing allows the patient to turn and move in bed and to walk without tension on the chest tube. It also minimizes the chance that a deep breath could draw any drainage back up into the chest. Sometimes two chest tubes are attached to a single patient tube and chest drainage system with a Y-connector.

Reusable Chest Drainage Systems

The first chest drainage systems were made up of a series of one to three interconnected reusable glass bottles. Although one-piece molded plastic drainage units have largely replaced these systems today, the principles on which the bottle systems were based hold true for today's integrated chest drainage systems.

■ One-Bottle Chest Drainage System

The simplest way to drain the chest is to set up a single bottle with a tube submerged to a depth of 2 centimeters under water as illustrated in Figure 6. One short tube leads out of the bottle through the plug at the top, allowing air to vent to the atmosphere. The submerged tube is connected to the patient tubing. Placing the distal end of the tube under water creates a water seal, the most important element in a pleural drainage system. The water seal provides a low-resistance, one-way valve that allows air to leave the chest while preventing outside air from being pulled into the chest during breathing.

Positive pressure exceeding $+2\text{cmH}_2\text{O}$ will push air down the tube. The air will bubble through the water and leave the chest drain system through the atmospheric vent.

If the tube that is submerged in the water is marked, indicating each centimeter on the tube, the water seal becomes a manometer that can measure intrapleural pressures. Pressure changes in the pleural space that occur with breathing will be seen as fluctuations in the level of the water within the tube. These fluctuations, called "tidalling," may be as great as 5 to $10\text{cmH}_2\text{O}$ with normal spontaneous breathing. The water level will go up (more negative) during inspiration, and go down (return to baseline) during exhalation. If the patient is receiving positive pressure ventilation, the water level will go down (more positive) during inspiration, and go back up (return to baseline) during exhalation, reflecting the higher positive pressure in the chest with mechanical ventilation.

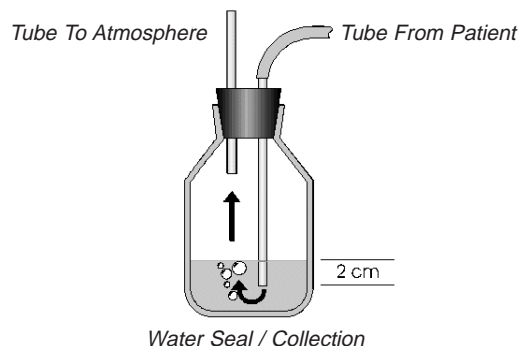


Figure 17. One bottle chest drain system

The one-bottle setup is a combination water seal and fluid collection bottle. As fluids drain from the chest into the bottle, the level of the initial sterile fluid combined with drainage will rise. Thus, the submerged tube will be deeper than 2 centimeters. The higher the fluid level, the more pressure it takes to push air through the fluid as it leaves the chest. Theoretically, the problem could be solved by emptying some of the drainage from the bottle or pulling the tube further out of the top of the bottle in an effort to maintain the $2\text{cmH}_2\text{O}$ water seal level. However, in practice, if fluid drainage is expected, another bottle is added to collect drainage independent of the water seal. This creates a two-bottle chest drainage system.

■ Two-Bottle Chest Drainage System

In a two-bottle chest drainage system, fluid drains from the chest into a dedicated collection bottle. Air from the pleural space, continuing through the tubing that connects the two bottles, bubbles through the water seal and exits to the atmosphere, as illustrated in Figure 18.

If the collection bottle has volume markings, the amount and rate of fluid drainage can be measured and monitored. More importantly, adding a separate collection bottle allows the water seal to remain at an undisturbed, fixed level, allowing air to leave the pleural space through a system with low resistance to air flow, regardless of the amount of fluid drainage.

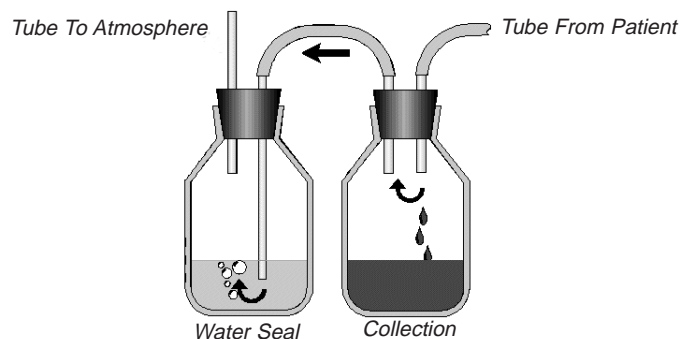


Figure 18. Two bottle chest drain system

Both the one- and two-bottle chest drainage systems rely on gravity to create a pressure gradient by which air and fluid leave the chest. Keeping the drainage system below the level of the patient's chest enhances gravity drainage; additional pressure is created when the patient exhales or coughs. However, if the patient has a large air leak into the pleural space, gravity drainage may not be sufficient to evacuate the chest, and suction may be required. This also means the addition of a third bottle to the system — a suction control bottle.

■ Three-Bottle Chest Drainage System

When suction is required to increase the pressure difference between the pleural space and the drainage system, it is important to accurately regulate suction levels to avoid patient injury. If suction pressure is too high, complications can occur such as hematoma formation at the distal end of the catheter and tissue invagination into the catheter eyelets.

A third bottle added to the chest drainage system will limit the amount of negative pressure that can be transmitted to the patient's chest. A suction control bottle has three tubes (see figure 19 on the next page) :

1. A long tube positioned so that the upper end is open to the atmosphere through the plug in the top of the bottle while the lower end is submerged under water, usually to a depth of 20 centimeters.
2. A short tube connected to the water seal bottle.
3. A tube that connects the bottle to the suction source, which can be either a portable pump or a wall vacuum regulator.

When the three bottle set-up is used as illustrated in Figure 19, the maximum level of negative pressure that can be

transmitted to the patient's chest directly corresponds to the depth of submersion of the tube in the suction control bottle. If the tube is under 20 centimeters of water, the maximum suction level the patient can be subjected to is -20cmH₂O.

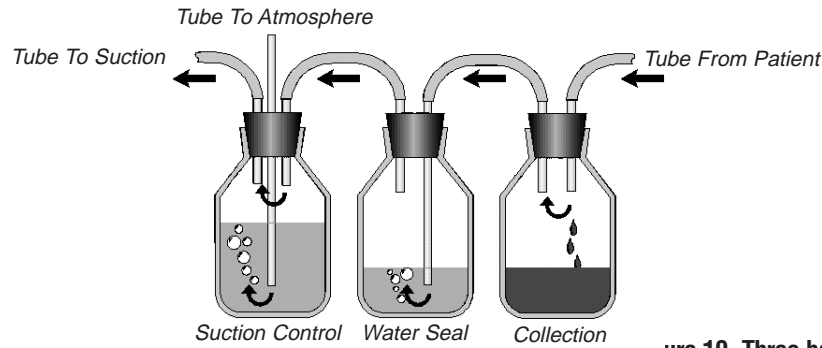


Figure 19. Three bottle chest drain system

tem

■ Suction Control Bottle

If the system is not connected to a vacuum source, the fluid in the suction control bottle's atmospheric vent tube will be at the same level as the fluid in that bottle and there will be no bubbling. If the system is connected to a vacuum source set at the same setting as the water level in the suction control bottle (-20cmH₂O, for example), the water in the atmospheric vent tube will be pulled down 20 centimeters below the surface of the water in the bottle, there will be no bubbling, and the pressure in all three bottles will be -20cmH₂O.

When the vacuum source is set at a level higher than the water level in the suction control bottle, the controlled maximum suction imposed on the patient is achieved when fluid is no longer present in the atmospheric vent tube and bubbling occurs in the bottle. Air is drawn in through the atmospheric vent. The air bubbles out the bottom of the submerged tube, and then is evacuated from the system through the vacuum source. The key is that the depth of submersion of the tube in the suction control bottle determines the amount of suction imposed on the patient.

■ Drawbacks of the Three-Bottle System

Three-bottle reusable systems have many clinical drawbacks. Set-up is time consuming, and because of all the connections, the potential for error or contamination of the sterile system is high. It can be expensive for the hospital to clean, sterilize and track the processing of the system and all of its pieces. Since there are no valves to vent positive and negative pressure build-up, the patient does not have the advantages of the safety advances made in disposable chest drainage systems over the past twenty years. These problems are solved with the one-piece, integrated disposable chest drain system.

Disposable Chest Drainage Systems

The first one-piece, disposable three-chamber chest drainage unit was introduced in 1967. Today's chest drainage systems are compact, sterile, and disposable. They offer many safety features, diagnostic capabilities and conveniences not found in the traditional three-bottle chest drain system. Figure 20 shows a schematic illustration of the one-piece chest drain system.

The chambers of these one-piece disposable units correspond to the bottles in the three-bottle system. Most one-piece disposable systems include:

- A collection chamber into which fluids drain and volume and rate of drainage can be measured
- A water seal chamber that uses sterile fluid or a mechanical one-way valve to allow air to leave the patient and prevent air from entering the patient's chest through the chest tube
- A suction control chamber that uses either sterile fluid or a mechanical device to control and limit the level of suction imposed on the patient.

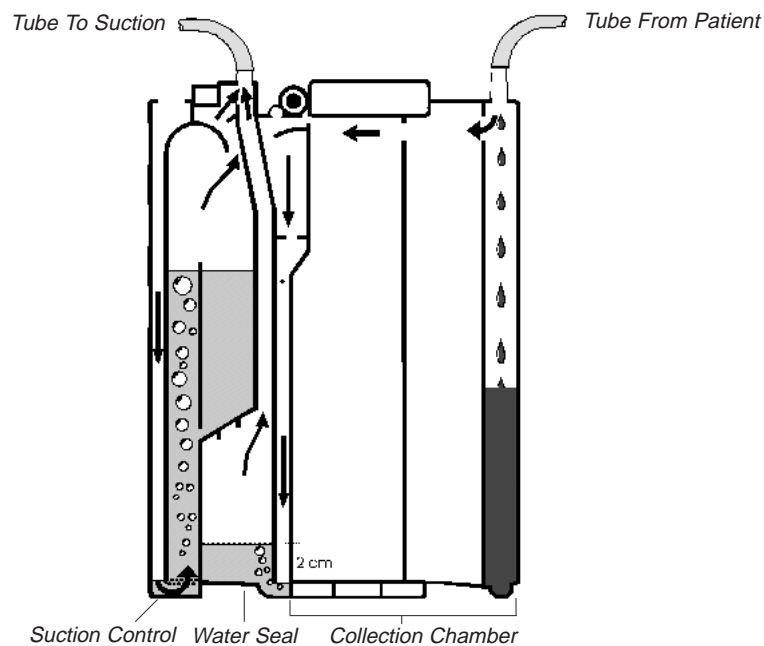


Figure 20. Conventional three-chambered disposable chest drain system

■ Collection Chamber

An easy-to-read, well-calibrated collection chamber permits the nurse to record the amount of fluid collecting in this chamber. Most drains allow the nurse to draw a line indicating the level of drainage and write the time on the front of the chamber. This allows all clinicians to assess the rate of fluid drainage from the chest.

■ Water Seal Chamber

▣ See Clinical Update: Dec 1997

The water seal chamber is connected to the collection chamber and provides the protection of the one-way valve discussed earlier. The water seal in most disposable drainage units is formed with an asymmetric U-tube rather than a narrow tube submerged underwater as in the traditional bottle systems. The narrow arm (closest to the collection chamber) is equivalent to the tube; the larger arm serves as the water reservoir. When the fluid reservoir is filled to 2 centimeters above the seal in the U-tube, it has the same effect as submerging the tube in the bottle system 2 centimeters below the surface of the water.

In addition to providing the one-way valve, a U-tube design can also be used to measure pressure. When pressures on both sides of the U-tube are equal, the water level is the same in both arms. However, if the pressures on each arm differ, fluid moves away from the side of higher pressure toward the side with lower pressure. If the water seal column on the front of the chest drain is calibrated with markings, the fluid movement acts as a water manometer for measuring intrapleural pressure, providing additional assessment data for the clinician.

Some units have an anti-siphoning float valve in the water seal fluid column that prevents the water from being siphoned out of the water seal chamber and into the collection chamber during situations that create high negative pressures, such as chest tube stripping. (This practice is not supported by research, but may be seen in the clinical setting.)

The original design of the float valve at the top of this chamber permitted uncontrolled vacuum levels to accumulate in the patient's chest with each subsequent stripping of the patient tube (see discussion on chest tube stripping on page 24). To eliminate this pressure accumulation (since tubes may still be stripped) manufacturers have added manual high negative pressure relief valves to chest drain systems that allow filtered atmospheric air to enter the system to prevent any accumulation of negative pressure in the patient. However, with manual devices, the clinician must recognize the condition of high negativity, evidenced by the rise in the water level in the water seal, and depress the relief valve to remedy the situation.

In 1983, automatic high negative pressure protection was introduced. Many systems now employ a float ball design at the top of the water seal chamber with a notch that allows fluid to pass through it. A compartment above the ball holds the water that fills the water seal chamber. Thus, no water spills into the collection chamber, and no water is lost, so the one-way valve protection is not put at risk during conditions of high negative intrapleural pressure. The speed at which disposable systems release accumulating negative pressure varies, depending on the manufacturer and a particular drain's design.

■ Dry Seal Chest Drains

▣ See Clinical Update: Jun 2000

Some chest drains use a mechanical one-way valve in place of a conventional water seal. The mechanical one-way valve allows air to escape from the chest and prevents air from entering the chest. An advantage of a mechanical one-way valve is that it does not require water to operate and it is not position-sensitive the way a water-filled chamber is. A dry seal drain protects from air entering the patient's chest if a drain is knocked over.

A drawback to any mechanical one-way valve is that it does not provide the same level of patient assessment information as a conventional water seal; for example, the clinician cannot see changes in the water level reflecting pressure changes in the chest. For optional air leak detection, a separate air leak monitor can be filled with water. A vacuum indicator on the face of the drain provides visual evidence of negative pressure (vacuum) inside the collection chamber.

■ Suction Control Chamber

▣ See Clinical Update: Mar 2008

The suction control chamber is another safety device that protects the patient from excess suction pressure in the pleural cavity or mediastinum. Suction control mechanisms in one-piece drains are either "wet" or "dry."

"Wet" suction control systems regulate suction pressure transmitted to the chest by the height of a column of water in the suction control chamber. Like the water seal chamber, the wet suction chamber is an asymmetric U-tube manometer. The narrow arm is the atmospheric vent and the large arm is the reservoir. *The amount of negative pressure that is transmitted to the patient's chest is determined by the height of water in this chamber, not the level of vacuum set on the wall (or source) regulator.*

"Dry" suction control systems regulate suction pressure mechanically rather than with a column of water. Some dry suction systems use a screw-type valve that varies the size of the opening to the vacuum source, thereby limiting the amount of negative pressure that can be transmitted to the chest. These valves narrow the opening of the chest drain in order to adjust the level of negative pressure; therefore, the total amount of air that can flow out of the chest drain is also limited. Thus, this type of dry suction control mechanism is impractical for patients with significant pleural air leaks.

Two manufacturers use a calibrated, spring-loaded, self-regulating mechanism that allows suction levels to be adjusted with the simple turn of a dial to the desired level of suction, in place of water (See Figure 21). These systems are capable of handling large volumes of airflow and can also compensate for changes in patient air leaks or fluctuations in the source vacuum while maintaining a consistent level of negative pressure in the patient's chest. The screw-type valves cannot compensate for these changes.



Figure 21. Dialing in desired suction level

Dry suction control mechanisms are quieter and often easier to set up than wet units. But because the dry unit is silent it is not as obvious that the unit is working properly without careful examination of the front of the drain. The sound of bubbling in wet units provides feedback that the system is working. Proper set-up and monitoring is covered in the next section.

If the tubing leaving the drain from the suction source becomes obstructed or if the source vacuum fails, and the patient has an active air leak from the pleural space, positive pressure could build up in the pleural cavity, significantly impairing breathing. This situation could even lead to a tension pneumothorax. To safeguard against this potentially life-threatening complication, most chest drain systems have a **positive pressure relief valve (PPRV)** that vents accumulated pressure greater than 2cmH₂O (the depth of the water seal).

■ Double Collection Chest Drains

Double collection chest drains are designed to be connected to two chest tubes. The drain consists of two collection chambers: a major chamber and a minor chamber. This type of drain is rarely used for chest tubes on both sides of the chest at the same time; rather, the tubes are on the same side of the chest. Typically, this drain is used when one tube is placed high in the chest to evacuate air, and one tube is placed low in the chest to drain fluid on the same side. Since the lower tube is likely to drain both fluid and air, it is connected to the major collection chamber. Since the upper tube will mostly evacuate air, it is connected to the minor collection chamber.

Double units may also be used in cardiovascular surgery when the surgeon wants to monitor drainage from two mediastinal tube locations separately. The tube(s) placed below the heart are connected to the major chamber and the tube(s) above the heart are connected to the minor chamber. Or, if a pleural tube is required because the parietal pleura was entered during cardiac surgery (particularly if the internal mammary artery is used for a bypass), the pleural tube can be connected to the minor chamber since it is placed to evacuate air. The mediastinal tubes, draining fluid, are then connected to the major chamber.

■ Infant Chest Drainage Systems

The most prominent feature of infant chest drainage units is the smaller collection chamber that holds less drainage than an adult unit. The patient tubing may have a narrower inner diameter compared with adult drains and usually has smaller connectors to connect the patient tubing to the smaller chest tubes used for infants.

■ Closed Wound Reservoirs

▣ See Clinical Update: Jun 2004

Closed wound drainage systems were originally designed to remove fluid from closed surgical sites; now they are being used for cardiothoracic surgical patients. Bulb suction reservoirs connect to the wound drain and create suction to evacuate fluid. It must be a completely closed system; any venting to the atmosphere will disrupt the system's self-generated suction. In a cardiothoracic patient, a closed system with no vent presents the potential for a catastrophic complication: tension pneumothorax. Chest drains vent to the atmosphere and have positive pressure relief valves for safety; wound drains do not. They can only be used after the lung is expanded and air leaks have sealed. However, not all air leaks are immediately apparent, particularly when there is no water seal or air leak indicator. Whenever an air leak is present, a drainage catheter must be attached to an appropriate pleural drainage system to prevent tension pneumothorax.

To use a bulb reservoir system, the reservoir is first "activated," creating unmeasured, unregulated suction that is transmitted to the surgical site. When a bulb reservoir is initially compressed and attached to a wound drain, it generates approximately $-120\text{cmH}_2\text{O}$ suction — far more than the carefully regulated $-20\text{cmH}_2\text{O}$ vacuum levels generated by a chest drain attached to a thoracic catheter. As the reservoir fills, tissues are exposed to varying levels of decreasing suction, and the bedside clinician has no way of knowing the level of suction being applied to the pericardial space or pleural cavity. As the reservoir fills, less negative pressure is present to draw fluid into the reservoir by suction, thus the flow rate of fluid and air leaving the chest will drop.

If the drain fills (100cc) and is not emptied immediately, the pressures between the surgical site and the reservoir will equalize. A pressure gradient between the patient and any drain (reservoir) is necessary for drainage. When pressures equalize, drainage stops. Thus, unlike a chest drainage system described earlier, a bulb reservoir system requires regular maintenance by the nurse to preserve patency. It must be emptied to maintain suction and keep drainage flowing. If pericardial drainage stops because the reservoir is filled, the patient is at risk for cardiac tamponade. Table 1 on page 12 compares the characteristics of a chest drain and a wound drain (reservoir) system.

Setting Up A Chest Drain System

Setting up a chest drainage system involves inserting the chest tube, setting up the drainage unit, making the proper connections and applying suction, as prescribed.

■ Thoracostomy

▣ See Clinical Update: Sep 2003 (part 1), Dec 2003 (part 2), Sept 2007, Dec 2007

The procedure for inserting a chest tube is called a **thoracostomy**. The precise location of the chest tube depends on whether the tube is to drain air, fluid or both. There is a difference of opinion among surgeons as to whether the incision should be made in the mid-axillary line or the mid-clavicular line.

Some avoid the mid-clavicular line because the pectoralis muscle is often very developed and difficult to penetrate, and to avoid a scar in such a prominent location on the front of the chest. These surgeons place the tube in the mid-axillary line and direct the distal end of the chest tube to the anterior location (See Figure 22).

- For most pneumothorax cases, the end of the tube is directed anterior and superior in the pleural space near the apex of the lung. Typically, this will be at the level of the second or third intercostal space.

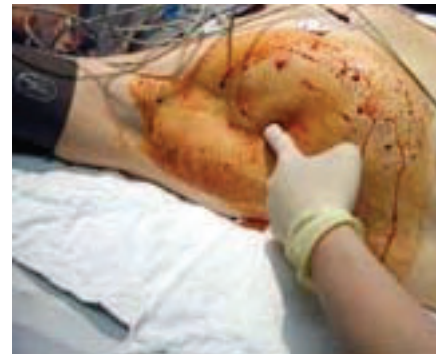

Figure 22. Chest tube insertion site in the R mid-axillary line

courtesy trauma.org

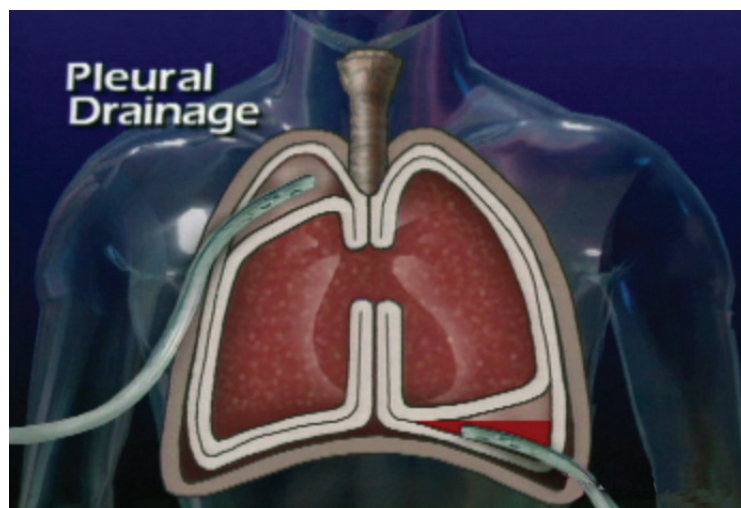


Figure 23. Chest tube placement: superior tube evacuates air, inferior tube drains fluid

- To drain a hemothorax or pleural effusion, the chest tube is directed inferior and posterior in the pleural space since gravity will pull fluid toward the base of the lung in a patient who is upright or in semi-Fowler's position. Again, the tube is placed in the mid-axillary line at about the seventh or eighth intercostal space.
- Frequently, two or more chest tubes are used, positioned at different locations within the pleural space to facilitate removal of all air and fluid. Figure 23 illustrates locations for chest tube placement.

When a chest tube is placed at the end of a surgical procedure, the open end of the chest tube is passed from the inside of the chest wall out through a small incision, leaving the end of the tube with eyelets for drainage strategically positioned within the chest for optimal drainage. A tight fit through the intercostal muscles is preferred to minimize bleeding and to achieve an airtight thoracic cavity closure.

In emergency situations, such as with spontaneous or traumatic pneumothorax, the chest tube is inserted directly through the skin and chest wall into the pleural space.

■ Steps for Chest Tube Insertion and Drain Setup

(The order of steps may be changed based on the patient's condition and the preferences of the clinician inserting the chest tube.)

1. Get the chest drain from storage; the chest tube (if not included in the insertion kit); and the chest tube insertion kit (or thoracostomy tray). Hospitals will determine the contents of an instrument tray from sterile processing or choose a disposable insertion kit. A kit may contain a syringe for local anesthetic, a skin antiseptic, sterile gloves, scalpels, hemostat(s), sutures and dressing material – if not, these supplies will need to be added to the sterile field. Check whether a local anesthetic such as lidocaine is in the kit or tray, or if unit stock is used instead.
2. Assure that the patient understands the procedure about to be done. Check that a consent form is completed and on the chart.
3. Check to see that the insertion site is marked, as required by the Joint Commission's Universal Protocol for Preventing Wrong Site, Wrong Procedure, Wrong Person Surgery™, according to hospital policy. If a chest radiograph is on the wall, two people should check to make sure the film is properly positioned on the view box and verify the right and left sides of the image.
4. Set up the chest drain according to the manufacturer's instructions for use. This may include adding water to the water seal chamber or air leak indicator and the suction control chamber.
5. As long as the procedure is not an emergency, requiring short cuts to save a patient's life, medicate the patient or begin procedural sedation (with proper orders or by protocol).
6. After the skin is cleaned and the local anesthetic injected, a small skin incision is made over the rib below the selected intercostal space. Dissection with a hemostat is carried out through the superior intercostal muscles and then into the pleural space. The catheter will then be inserted through this tract (See Figure 24). (When a trocar is used, a puncture is made through the intercostal muscles with the trocar stylet instead of using tissue dissection).

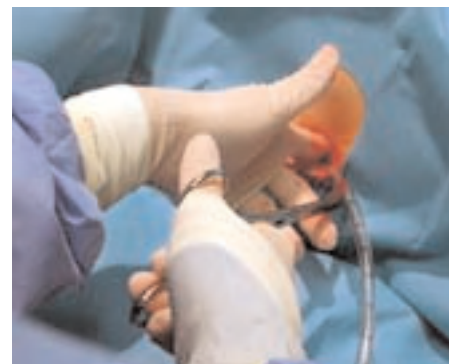

Figure 24. Inserting chest tube with clamp.
courtesy trauma.org

7. Once the chest tube is placed, it will be sutured in place (See Figure 25). The chest tube is typically clamped to prevent air from entering the chest until the tube is secured to the chest and connected to the chest drain system.
8. The open end of the chest tube is then attached to the stepped connector on the end of the patient tubing attached to the collection chamber of the chest drainage system.
9. The insertion site is covered with a sterile occlusive dressing. Pads designed as tracheostomy dressings — with the slit in the middle — are ideal for positioning around the chest tube itself. The British Thoracic Society's guidelines recommend using a transparent dressing to allow direct visualization of the insertion site and to reduce the risk of limited movement a bulky dressing can cause.
10. Place the chest drain below the chest tube, either by hanging it on the bed frame or by using a floor stand and placing it on the floor. Mobile drains should be positioned according to manufacturer's instructions for use.
11. If suction is ordered, attach the suction tubing from the chest drain to a vacuum source (typically a wall vacuum regulator). Use connecting tubing if needed. If a wet suction control system is used, slowly increase source vacuum (suction) until constant gentle bubbling occurs in the suction control chamber. For dry suction control units, set the dial to the prescribed level of suction, and increase source vacuum until the indicator — a small bellows or float — appears in the indicator window and the vacuum source is set at least -80mmHg.
12. Confirm that a radiograph has been ordered to check the position of the chest tube and to evaluate resolution of the pneumothorax or fluid removal.

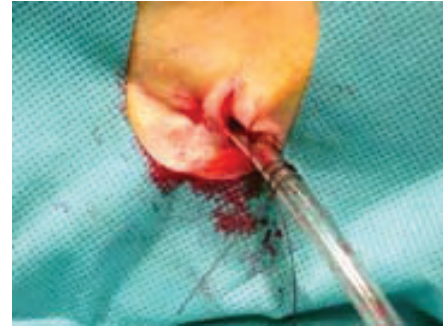

Figure 25. Sutures used to secure the tube to the chest wall.

courtesy trauma.org

Caring For Patients Requiring Chest Drainage

▣ See Clinical Update Dec 2007

After chest drainage has been initiated, the nurse should perform regular patient assessments. The frequency will depend on the reason chest drainage is required, the patient's condition and any comorbidities present such as underlying lung disease.

■ Respirations

Note the rate, regularity, depth and ease of respirations. Listen for changes in breath sounds, paying particular attention to the symmetry of sounds. If breath sounds are asymmetrical, double check the chest drainage system to assure it is patent and working properly. Diminished breath sounds on the affected side may indicate re-accumulation of air or fluid in the pleural space.

Every hour or two, have the patient take in deep breaths and cough. Explain that this helps keep the lungs expanded and makes breathing easier.

Be sure to teach splinting of the thoracic incision if you are caring for a postoperative patient. When the patient coughs, have him or her place a pillow over the incision and squeeze or hug the pillow close to the chest wall during coughing.

■ Knowledge Level

Continually assess the patient's understanding of the use of the chest tube and the postoperative regimen of care. If your institution provides a patient version of a clinical pathway for bypass surgery, for example, review it with the patient regularly.

■ Pain Control

Since the parietal pleura is innervated by intercostal nerves and is very sensitive to pain, regular pain assessments are critical to successful care of the patient requiring chest drainage. Failure to adequately manage incision pain or pleural pain can lead to hypoventilation, putting the patient at much higher risk for complications such as atelectasis and pneumonia. Also be aware of the risk of hypoventilation associated with opioid analgesics and patient-controlled analgesia. Some surgeons use local nerve blocks for pain management to reduce opioid side effects.

■ Vital Signs

Monitor vital signs regularly. If the patient has mediastinal chest tubes, be sure to listen to the quality of heart tones. Muffled or distant heart tones are one sign of cardiac tamponade.

■ Patient Position / Movement

▣ See Clinical Update: Dec 1998, March 2005, June 2007

Research shows that patients who get out of bed and walk around postoperatively will have fewer complications and

shorter lengths of stay. According to the American Hospital Association, in 2004, the average cost of a patient day in an acute care hospital was \$1289.87. Even reducing length of stay by one-half day results in significant cost savings. Unfortunately, many patients who need chest drainage are tethered to wall vacuum because it has been assumed that pulling air and fluid out of the chest rather than using gravity drainage will hasten recovery. In recent years, however, this practice has been examined to see if, indeed, suction is required.

One research study examined pulmonary resection patients and compared continuous suction to discontinuing suction for gravity drainage on postop day 2. In the gravity drainage water seal group, 67% of air leaks resolved one day after wall vacuum was discontinued. In patients who had continuous suction, only 7% of air leaks resolved by postop day 3.

A subsequent study compared patients after pulmonary wedge resection. This time, all patients were connected to wall vacuum in the operating room to re-expand the lung at the end of the case, then vacuum was disconnected for transport to the PACU. There, patients were randomized to resume vacuum or to stay on gravity water seal drainage — two days earlier than in the previous study.

The researchers found that the duration of air leaks in the gravity water seal group was about one-half the time of the wall vacuum group. Since many argue that suction is critical for apposition of the pleurae postoperatively, these researchers initially used suction on all patients in the operating room. These researchers note that on inspection, bubbling is more vigorous in the water seal chamber when the chest drain is connected to wall vacuum, indicating a greater flow of air out of the lung. By switching to gravity drainage, airflow is reduced which allows the lung suture line to be more closely approximated, and speeds healing. They state that routinely using wall vacuum postoperatively is counterproductive.

If a chest drain is disconnected from suction, be sure the tube is open to the air. Disconnect the extension tubing used to reach the vacuum source. Do not clamp this tube. If there is a stopcock on the tubing, it should be in the open position. ■ See Clinical Update: Sep 2002

Any drain should be kept below the level of the chest tube to facilitate gravity drainage. Most drains have a carry handle that allows the patient to carry the drain while walking. One manufacturer makes a holder for drains that attaches to the bottom of an IV pole. The drain simply slips into the holder and is automatically held in the proper position.

While the patient is in bed, enhance drainage by changing the patient's position regularly and placing him or her in high- or semi-Fowler's position to facilitate gravity drainage of pleural fluid.. Coil tubing on the bed, and let it fall in a straight line to the collection chamber of the chest drain. Avoid dependent loops in the patient tubing since they can impede drainage from the chest.

The chest tube should **not** be clamped during patient movement, ambulation, or during trips to other parts of the hospital. Clamping the chest tube blocks drainage, which could result in a tension pneumothorax or cardiac tamponade. Clamp chest tubes only to:

- Locate an air leak
- Simulate chest tube removal (to assess patient's tolerance)
- Replace a drain
- Connect or disconnect an in-line autotransfusion bag

■ Chest Tube Site / Dressing

Regularly assess the chest tube insertion site. Check to see that the dressing is dry and intact, and palpate around the dressing and the insertion site for subcutaneous emphysema that could indicate air escaping from the pleural space and into the subcutaneous tissues (See Figure 26).

If subcutaneous emphysema is present, take down the dressing and carefully inspect the site where the chest tube leaves the chest wall. Look for any evidence drainage eyelets may have pulled out of the pleural space, such as broken sutures. Tube movement can allow air to enter the subcutaneous tissue. If eyelets are visible, the chest tube will need to be repositioned. If no eyelets are visible, re-dress the site. In both cases, notify the physician.

If the dressing is soiled with drainage, change it as necessary. Otherwise, leave the dressing in place and do not change it regularly unless required by hospital policy. There are no research data guiding the decision whether to use petrolatum gauze underneath the dry sterile dressing.

A semi-conscious or agitated patient may pull the tube out of the chest. If the patient had an air leak from the chest tube, indicated by bubbling in the water seal chamber, cover the site with a sterile dressing. Tape it on only three sides, allowing air to escape through the fourth side, preventing air accumulation and the risk of tension pneumothorax. Stay with the patient while a colleague calls the physician STAT and gets the equipment so a new tube can be placed. If there was no air leak evident at your last assessment, apply a sterile occlusive dressing and monitor the patient carefully for any signs of respiratory distress. Notify the physician, who will typically order a chest x-ray to see if the lung is expanded and if the patient needs to have a chest tube inserted.

■ Tubing

Regularly inspect the drainage tubing for leaks, kinks, fluid-filled dependent loops, or compression or occlusion and trace the tubing from the chest wall to the collection chamber of the chest drain.

Check tubing connections any time a patient returns from a trip off the nursing unit; for example, after going to the radiology department. If the tubing comes apart, clean the ends with an alcohol wipe and reconnect them. Ask the patient to cough a few times to push any residual air out of the pleural space.

Research has shown that chest tube manipulation (stripping or milking) does not enhance bloody drainage from the chest (see Suggested Readings). A current Cochrane review states there is not enough evidence to support the practice. Blood that comes in contact with the pleurae or pericardium becomes defibrinogenated and should not clot; that's why this shed blood can be used for autotransfusion. Furthermore, research shows that stripping chest tubes can generate pressures as high as $-400\text{cmH}_2\text{O}$, which can suck lung tissue into the drainage eyelets in the end of the chest tube. Remember, typical suction pressure is $-20\text{cmH}_2\text{O}$.

Tube manipulation should be limited to situations in which patients are receiving medication or blood products that will enhance clotting, or when a blood clot or tissue fragment is visible in the tube and poses the risk of tube occlusion.

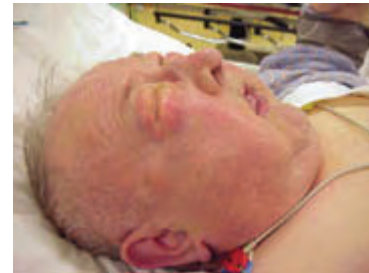

Figure 26. Subcutaneous emphysema related to chest drainage can also dissect through fascial planes and into the face.

courtesy trauma.org

Use gentle techniques, such as squeezing hand over hand along the tubing and releasing the tubing between each squeeze. Alternatively, small sections of tubing can be fan-folded and squeezed together, then released. Begin at the patient and work down the tubing to the chest drain. Be particularly careful in patients with fragile lung tissue such as in emphysema. The automatic high negative pressure relief valve on many chest drains will help protect the patient from exposure to high negative pressures caused by vigorous manipulation of the chest drainage tubing. However, there is no evidence that supports tubing manipulation during routine patient care.

■ Drainage Fluid

Depending on hospital policy, samples of drainage fluid may be taken by inserting a needle (20 gauge or smaller) attached to a syringe directly into the patient drainage tube (See Figure 27). Alternatively, on selected chest drain models, samples can be taken directly from the luer-lock needleless access port located on the patient tube.

Regularly monitor the volume, rate, color and characteristics of the collected drainage. Mark the level, time and date on the face of the collection chamber at regular intervals. The frequency will be determined by the reason the patient has the chest tube and the volume and rate of drainage. Most one-piece chest drainage units are designed with a write-on surface; the calibrations of the drainage measurements will vary by manufacturer and type of drain (adult or pediatric/infant).

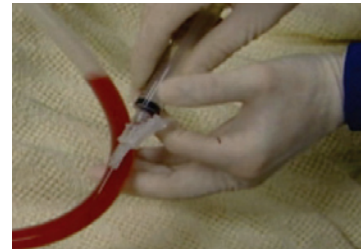


Figure 27. Withdrawing a drainage sample from the patient tube

Drainage volume from bleeding is usually relatively small. Over 100mL/hour postoperatively is considered excessive drainage; even bleeding after chest trauma is seldom more than 200 to 300 mL/hr. If drainage is greater, the patient will likely have an exploratory thoracotomy. After cardiac surgery, mediastinal drainage is usually less than 300mL in the first hour, less than 250mL in the second hour, and less than 150mL/hr after that. Always monitor the patient for the unexpected situation in which there is significant postoperative bleeding that may require immediate intervention and an urgent trip to the operating room.

Be aware that bloody drainage can collect in the pleural space until the patient moves into a more favorable position for gravity drainage. If you suddenly see increased drainage, particularly after position change, check the color of the drainage. If it's dark, it is old drainage; fresh drainage will be more red in color. This type of drainage typically lasts for a few minutes.

■ Water Seal

Check periodically to see that the water seal is filled to the appropriate level, and that the water level moves as the patient breathes (tidalling). If there is no tidalling, it could mean that:

- The tubing is kinked
- The tubing is clamped
- The patient is lying on the tubing
- There is a dependent, fluid-filled loop in the tubing
- Lung tissue or adhesions are blocking the catheter eyelets
- No air is leaking into the pleural space and the lung has re-expanded




Figure 28. Water seal with air leak meter

When you first apply suction, there should be a little bubbling in the water seal (or the air leak monitor in a dry seal chest drain system) as air is pulled through from the collection chamber. If no other air enters, the bubbling should soon stop. Bubbling continues when air is entering the system. If an air leak is not expected from your patient assessment, there may be a leak in the system – somewhere between the chest tube and the drain itself. To locate the leak, clamp the tubing with a special tubing clamp or rubber-tipped (booted) hemostat. Start by clamping the chest tube where it leaves the chest, and work your way down to the collection chamber. Leave the clamp in place no longer than ten seconds while you glance at the water seal chamber. Once the clamp is placed between the air leak and the water seal, the bubbling should stop.

Proceed as follows:

1. Clamp the tube where it leaves the dressing. If the bubbling stops, the leak is likely from the lung/pleural space. However, the tube itself may be displaced. If the bubbling is new and unexpected, take down the dressing and examine to see if a drainage eyelet has moved outside the chest wall as discussed earlier on page 25.
2. If the bubbling continues when you place the clamp at the chest wall, place the clamp on the patient side of the connector between the chest tube and the tubing leading to the chest drain. If bubbling stops, the leak is between the patient and the clamp.
3. If bubbling continues, move the clamp to the other side of the connector. If bubbling stops, the leak is likely coming from the connector. Check to see that the tubing is attached tightly on each side of the connector and push the tubing and connector together as tightly as possible. Then look to see if bubbling stops. If necessary, replace the connector.
4. If bubbling persists when you place the clamp on the drain side of the connector, the leak could be coming from a hole or puncture in the patient tubing.
5. If bubbling does not stop after you have clamped at intervals all the way down the tubing, the drainage unit may be cracked and may need to be replaced.

■ Suction

Check suction connections and tubing routinely to ensure the tubing is patent and the system is operating properly. Check that the suction control chamber on the drain is set at the level ordered, or according to protocol. Typically, the suction level on the drain is -15 to -20cmH₂O for adults; lower levels may be used for children, although there are no research studies to guide practice in this area.

If the chest drain uses a wet suction control mechanism, pinch the suction tubing closed momentarily to stop bubbling so you can see the water level in this chamber. Adjust the vacuum source (typically a wall regulator) so that there is gentle, continuous bubbling in the chamber. Bubbling that is too vigorous makes a lot of noise, which could disturb the patient with the chest tube as well as other patients nearby. Vigorous bubbling will cause faster evaporation and water may need to be added to maintain the desired level of suction control.

Dry suction chest drain systems that use the screw-type valve mechanism to regulate suction levels do not automatically compensate for changes in the patient's air leak or changes in vacuum source pressure the way the other dry suction drain mechanisms do. Therefore, it is important to check the suction indicator frequently to watch for unintended changes in imposed suction.

Most one-piece chest drains have a positive pressure relief valve that prevents excess pressure from building up in the system. If someone inadvertently steps on the suction tubing, for example, or if equipment should roll over it, pressure will be vented through this valve, reducing the risk of tension pneumothorax.

Disconnecting The Chest Drainage Unit

The chest drainage unit is usually disconnected and is typically replaced when the collection chamber is full, when the patient's condition has healed, or when the unit is cracked or broken.

To replace a unit, follow these steps:

1. Prepare the new unit, adding water where needed.
2. Untape and slightly loosen the connection between the chest tube and the stepped connector so you know you can disconnect the two when you are ready to change the drain.
3. Ask the patient to perform a Valsalva maneuver to force air out of the pleural space and keep air from entering while you switch the tubing. If the patient cannot do this, make the switch at the end of exhalation if the patient is breathing spontaneously or the end of inspiration of a machine-generated breath.
4. Using sterile technique, clamp off the chest tube and quickly disconnect the old drainage tubing from the chest tube and replace it with new tubing connected to the new drain. (Some hospitals don't call for a clamp; follow your institution's policy and procedure guide.) Tell the patient to breathe normally when you are done and take off the clamp. Be sure to keep the clamp in plain sight so you don't forget about it. If you have trouble getting the connectors apart, take the clamp off, let the patient breathe normally, and start over.
5. Dispose of the chest drain unit according to hospital policy and procedure, following standard precautions.

In the unlikely event that the drainage unit is accidentally broken, disconnect it from the chest tube and submerge the end of the chest tube a few centimeters below the surface of a bottle of sterile water or saline. This will provide a temporary water seal to protect the patient while a new drainage unit is being set up.

Removing The Chest Tube

▣ See Clinical Update: Dec 2000 and Dec 2006

The chest tube can be removed when:

- Drainage diminishes to little or nothing
- Any air leak has disappeared
- Fluctuations in the water seal chamber stop
- The patient is breathing normally without any signs of respiratory distress
- Breath sounds are equal and at baseline for the patient
- Chest radiograph shows the lung is re-expanded and there is no residual air or fluid in the pleural space

About 8 to 12 hours before the chest tube is removed, the physician may order that the chest tube be clamped for several hours to simulate chest tube removal and assess the patient's response. A chest radiograph may be taken about 2 hours after the tube is clamped to verify that the lung has re-expanded and that there is no significant residual air or fluid in the pleural space. However, recent research has shown that clinical assessment identifies respiratory compromise from air or fluid, and that a chest radiograph is not needed if the assessment is normal. Monitor the patient's respiratory status carefully during this time, and unclamp the tube if the patient develops signs or symptoms of respiratory distress.

The chest tubes are usually removed at the bedside. Prepare for the tube removal by collecting a suture set, petrolatum gauze, 4 x 4 sterile gauze pads and occlusive tape. Any other equipment will be specified by physician preference or hospital policy and procedure. Medicate the patient as ordered (see the Suggested Readings for nursing research about sensations associated with chest tube removal).

Once the dressing is removed and the anchoring (stay) suture is cut, the patient will need to exhale and perform a Valsalva maneuver to increase intrathoracic pressure as the tube is pulled out. The tube will be pulled out quickly, and the skin closure suture pulled tight to close the wound. The British Thoracic Society recommends against purse-string sutures because they turn a linear wound into a circular wound that is more uncomfortable for the patient and takes longer to heal. Once the tube is removed, the patient can then breathe normally. The prepared dressing will be placed over the site and should be taped as an occlusive dressing. A chest radiograph may be done shortly after the procedure to assure that the lung remains expanded. Monitor the patient frequently for any signs of respiratory distress after tube removal, and then at longer intervals if the assessment remains normal.

Autotransfusion

A patient who is bleeding heavily postoperatively or preoperatively, from chest trauma may need to be transfused (See Figure 29). Reinfusion of the patient's own blood, called **autotransfusion**, may be used as an alternative to transfusing banked blood. The blood is readily available, does not need to be crossmatched, and is easy to collect and rapidly reinfuse.

Most chest drain manufacturers have an optional in-line blood recovery bag that can be connected between the drainage tubing and the collection chamber so that the blood will drain into the bag before it gets to the collection chamber. When enough blood has been collected, disconnect the bag from the patient and the drainage unit, attach filtered blood tubing and administer the blood to the patient.

Another option is closed loop, or continuous autotransfusion (ATS). In this method, an **infusion pump** is used to reinfuse the blood instead of the blood recovery bag. Shed blood that collects in the ATS collection chamber can be given back to the patient by connecting IV tubing to a port in the bottom of the chamber and using a blood-compatible infusion controller to administer the blood to the patient. This can be done hourly or on a continuous basis.

The third alternative is the self-filling ATS bag. The self-filling bag can pull blood out of the collection chamber, allowing for the most rapid autotransfusion blood collection during emergency situations where high volume blood loss occurs in a short period of time — either postoperatively or during trauma resuscitation. This approach is particularly beneficial if the amount of blood loss into the drain is unexpected; with the self-filling bag, that blood is no longer wasted in the drain until a drainage bag can be attached to the drainage tubing.

Be sure to follow all hospital policies, procedures, and protocols for handling blood, administering anticoagulants, **autologous** whole blood autotransfusion, pressure blood infusion, disposal, and infection control. Follow the manufacturers' instructions for use, warnings and cautions for anticoagulant medication, transfusion filters, blood infusion sets, blood-compatible infusion pumps, and pressure infusion devices prior to using any blood collection and reinfusion system. Manufacturers have limits on the amount of pressure that can be used for pressure infusion; be sure to check the instructions for use for the particular bag you are using.

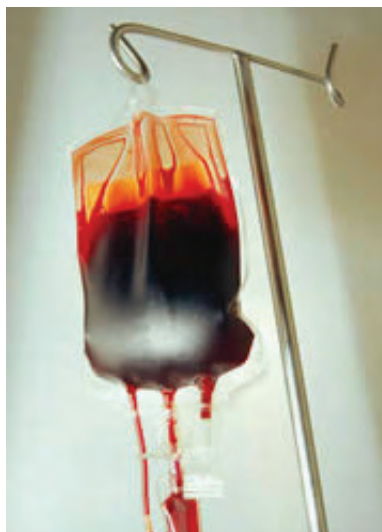

Figure 29. Blood transfusion

The Future Is Now: Mobile Chest Drains

▣ See Clinical Update: Mar 2002 (part 1), June 2002 (part 2), March 2005, June 2007

Chest drainage technology has followed trends in today's healthcare system. One of the most prominent of these trends is the move to reduce patients' lengths of stay in acute care hospitals. Shorter stays mean lower cost of care. This has led to routine fast-track programs for both cardiac and general thoracic surgery patients.

Getting patients up and walking is a critical step toward the goal of early discharge. That's difficult to accomplish if the patient is tethered to a wall suction source or has a relatively large chest drain to carry around. This challenge has led to the development of mobile chest drains.

There are two types of mobile chest drains: one for air alone and one for both fluid and air. Mobile chest drains used to treat pneumothorax are one-way valves that allow air to leave the chest and not re-enter. The current recommendations from the American College of Chest Physicians state that patients without underlying lung disease who have small pneumothorax and are reliable for follow up may go home with a one-way valve in place. These mobile drains may be used to facilitate ambulation and reduce length of stay in hospitalized patients as well.

The first device for mobile chest drainage was the Heimlich valve, which consists of a flattened Penrose drain housed in a plastic cylinder that acts as a one-way valve. When it was introduced in Vietnam in the 1960s, it didn't matter that the device could not contain fluid drainage. To meet today's needs for a device to manage uncomplicated pneumothorax, one manufacturer has designed a latex-free, lightweight, portable device that contains a one-way valve (so air can leave the chest and not re-enter) and a 30cc fluid reservoir that collects pleural fluid so that standard precautions are maintained (See Figure 30).

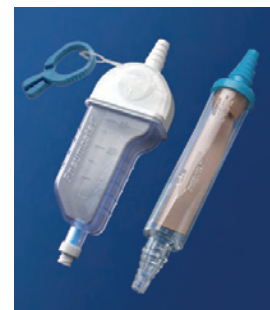

Figure 30. Closed mobile drain (L) and Heimlich valve (R)

For postoperative patients who do not have significant fluid drainage, or for those who can be stepped down to a mobile device, a mini chest drain is now available. One manufacturer's device has a 500cc collection chamber, a mechanical one-way valve in place of a water seal, an air leak monitor, and a mechanical suction regulator in a device that measures 8.5 inches tall, 5 inches wide and 1.25 inches deep. The drain can be "worn" by the patient with straps that can go over the shoulder or around the waist to encourage ambulation when suction is not required (See Figure 31).

The first study that used mobile, mini chest drains to send patients home with prolonged air leaks after surgery was reported from Indiana University Hospital in 2005. Previously, these patients remained in the hospital, tethered to a traditional chest drain.

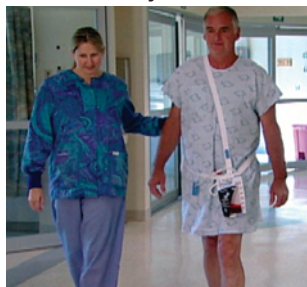

Figure 31. Mini mobile drains allow for ambulation

Over 20 months, 10% (n=50) of patients met criteria to go home; 7.8% (n=36) did go home with a mini drain. This approach saved 404 days of hospitalization. At \$1,289.87 (average) per day, the savings over 20 months were about \$500 thousand. There were no significant complications and patient satisfaction was very high.

This newly emerging technology is designed to meet the needs of today's healthcare sys-

tem as surgical technology changes to allow for less invasive cardiothoracic procedures. A preliminary study from the University of North Texas Health Science Center that examined using the mini chest drain showed a 72% reduction in the delay until full ambulation in patients with pulmonary wedge resection and a 40% reduction in length of stay. Look for more studies about the relationship between the portability of chest drainage systems, early ambulation and length of stay in the future.

Summary

You have just reviewed the principles of chest drainage and the steps involved in implementing safe, effective care for your patients. Incorporating this knowledge into your daily practice will help you manage patients with chest tubes more confidently, and allow you to help choose chest drainage systems and devices that best meet the needs of your patients, your hospital and your health care system.

Glossary

Alveoli	Thin-walled, sac-like dilations of the bronchioles, alveolar ducts, and alveolar sacs, across which gas exchange occurs between alveolar air and the pulmonary capillaries.
Autologous	Originating with the same individual, especially from the tissues or fluids (e.g., autologous blood).
Autotransfusion	Procedure in which blood is collected from a patient and reinfused into that same patient's circulation. Also known as autologous autotransfusion.
Bronchus	One of the larger branches of the trachea, a connecting airway that leads to the lungs.
Cardiac Tamponade	External compression of the heart by fluid in the pericardial sac, eventually limiting filling capacity, venous return and cardiac output.
Chylothorax	Accumulation of milky lymphatic fluid in the pleural space, usually on the left.
Diaphragm	Musculomembranous partition between the abdominal and thoracic cavities.
Dyspnea	Shortness of breath; a subjective difficulty or distress in breathing, usually associated with disease of the heart or lungs.
Emphysema	Increase in the size of the air spaces distal to the terminal bronchioles, with destructive changes in their walls and reduction in their number.
Empyema	Presence of pus in a pleural cavity. Also called Pyothorax.
Exsanguination	Excessive loss of blood due to internal or external hemorrhage.
Hemopneumothorax	Accumulation of air and blood in a pleural cavity.
Hemothorax	Collection of blood in a pleural cavity, usually the result of traumatic injury.
Infusion Pump	Device that controls the rate of fluid delivered to the patient through a vascular access device.
Intercostal	Between the ribs.

Manometer	Instrument that measures liquid or gaseous pressure. The measurement is usually given in millimeters of mercury (mmHg) or centimeters of water (cmH ₂ O).
Mediastinal Shift	Compression of the central mediastinal cavity toward the opposite lung in response to a tension pneumothorax. May lead to collapse of the lung and compression of the large veins that return blood back to the heart, decreasing blood pressure and causing extreme respiratory distress.
Mediastinum	Space between the two lungs that contains the heart and its large vessels, the trachea, esophagus, thymus, lymph node, and other structures and tissues.
Pericardium	Membranous sac covering the heart. It has two layers that form a potential cavity known as pericardial cavity or pericardial sac.
Pleura	Serous membrane enveloping the lungs and lining the walls of the pleural cavity. Parietal pleura: the pleura that lines the different parts of the wall of the pleural cavity. Visceral (pulmonary) pleura: the pleura that covers the lungs.
Pleural Effusion	Escape of fluid from the blood vessels or lymphatics into the pleural space.
Pleural Space	Potential space between the parietal and pulmonary pleurae.
Pneumothorax	Presence of air or gas in the pleural cavity. Closed pneumothorax: Air enters the pleural space from an opening in the lung. The chest wall remains intact. Open pneumothorax: An opening in both the chest wall and the lung that allows air to enter the pleural space. Also called a sucking chest wound. Spontaneous pneumothorax: Air enters the pleural space without obvious trauma to the lung or chest wall; most common in patients with advanced emphysema and blebs, or in young, tall men after a growth spurt. Tension pneumothorax: Air is trapped in the pleural space, is trapped, and during exhalation, intrathoracic pressure builds to levels higher than atmospheric pressure. This pressure build-up compresses the lung and may displace the mediastinum toward the opposite side.
Positive Pressure Relief Valve (PPRV)	A valve on a chest drain that prevents pressure above atmospheric pressure from building up in the system.
Postoperative Autotransfusion	Collection and reinfusion of the patient's blood shed from the mediastinum, pleural cavity or joint space after surgery.
Pyothorax	See Empyema .
Serosanguineous	Liquid drainage that contains both serum and blood, usually pink or straw-colored.

Sternum	Breastbone.
Subcutaneous Emphysema	Presence of air in the interstices of the subcutaneous tissue.
Thoracostomy	Creating an opening in the thoracic cavity to drain unwanted air or fluid.
Thoracotomy	Incision into the chest wall.
Thorax	Chest; upper part of the trunk between the neck and the abdomen.
Trachea	Windpipe.

Suggested Readings

Adrales G, Huynh T, Broering B, et al.: A thoracostomy tube guideline improves management efficiency in trauma patients. *Journal of Trauma, Injury, Infection & Critical Care* 2002;52:210-216.

Akrofi M, et al: A randomized comparison of three methods of analgesia for chest drain removal in postcardiac surgical patients. *Anaesthesia Analgesia* 2005;100:205-209

Alphonso N, Tan C, Utlely M, et al: A prospective randomized controlled trial of suction versus non-suction to the underwater seal drains following lung resection. *European Journal of Cardiothoracic Surgery* 2005;27:391-394.

Anderson B, Higgins L, Rozmus C: Critical pathways: application to selected patient outcomes following coronary artery bypass graft. *Applied Nursing Research* 1999;12(4):168-174.

Antunes G, Neville E, Duffy J, Ali N: BTS guidelines for the management of malignant pleural effusions. *Thorax* 2003;58(Suppl II):ii29-ii38.

Ayed AK: Suction versus water seal after thoracoscopy for primary spontaneous pneumothorax: prospective randomized study. *Annals of Thoracic Surgery* 2003;75:1593-1596.

Baumann MH: Less is more? *Chest* 2001;120(1):1-3.

Baumann MH: What size chest tube? What drainage system is ideal? And other chest tube management options. *Current Opinions in Pulmonary Medicine* 2003;9:276-281.

Baumann MH, Patel PB, Roney CW, Petrini MF: Comparison of function of commercially available pleural drainage units and catheters. *Chest* 2003;123:1878-1886.

Baumann MH, Strange C, Heffner JE et al.: Management of spontaneous pneumothorax: an American College of Chest Physicians Delphi consensus statement. *Chest* 2001;119(2):590-602.

Beaulieu Y: Bedside ultrasonography in the ICU: part 1. *Chest* 2005;128(2):881-895.

Beaulieu Y: Bedside ultrasonography in the ICU: part 2. *Chest* 2005;128(3):1766-1781.

Berger P, Leemans R, Kuiper MA, van der Voort PHJ: Uncommon complications during chest tube placement: a potential role of tube material. *Intensive Care Medicine* 2003;29:1610-1611.

Brinelli A, Monteverde M, Borri A, et.al.: Comparison of water seal and suction after pulmonary lobectomy: a prospective, randomized trial. *Annals of Thoracic Surgery* 2004;77(6):1932-1937.

Broschious SK: Music: an intervention for pain during chest tube removal after open heart surgery. *American Journal of Critical Care* 1999;8(6):410-415.

Bruce EA, Howard RF, Franck LS: Chest drain removal pain and its management: a literature review. *Journal of Clinical Nursing* 2006;15:145-154.

Burrows CM, Mathews WC, Colt HG: Predicting survival in patients with recurrent symptomatic malignant pleural effusions. *Chest* 2000;117(1): 73-78.

Capps JS, Tyler ML, Rusch VW, Pierson DJ: Potential of chest drainage units to evacuate broncho-pleural air leaks. *Chest* 1985;88S:57S. [classic for discussion of physics]

Carroll P: A guide to mobile chest drains. *RN* 2002;65(5):56-60,65.

Carroll P: Ask the experts: dry suction chest drainage system. *Critical Care Nurse* 2003;23(4):73-74.

Carroll P: Chest drainage made easy. *RN* 1995;58(12):46-56.

Carroll P: Enhancing the safety of medical suction through innovative technology. *RTMagazine* 2008;21(2):30, 32-34. Available online at: http://www.rtmagazine.com/issues/articles/2008-02_04.asp

Carroll P: Exploring chest drain options. *RN* 2000;63(10):50-54.

Carroll P: Mobile chest drainage: coming soon to a home near you. *Home Healthcare Nurse* 2002;20(7):434-441

Carroll PF: Patients with pleural air leaks. *Focus on Critical Care* 1987;14(3):48-51.

Carroll PL: The principles of vacuum and its use in the hospital environment. 1995. Ohmeda, Inc.; Columbia, MD.

Cerfolio RJ, Bass C, Katholi CR: Prospective randomized trial compared suction versus water seal for air leaks. *Annals of Thoracic Surgery* 2001;71(5):1613-1617.

Cerfolio RJ, Bryant AS, Bass CS, Alexander JR, Bartolucci AA: Fast tracking after Ivor Lewis esophagogastrectomy. *Chest* 2004;126(4):1187-1194.

Cerfolio RJ, Bryant AS, Singh S, Bass CS, Bartolucci AA, et al: The management of chest tubes in patients with a pneumothorax and an air leak after pulmonary resection. *Chest* 2005; 128(2):816-820.

Cerfolio RJ, Pickens A, Bass C, Katholi C: Fast-tracking pulmonary resections. *Journal of Thoracic and Cardiovascular Surgery* 2001; 122(2):318-324.

Cerfolio RJ, Price TN, Bryant AS, Sale Bass C, Bartolucci AA: Intracostal sutures decrease the pain of thoracotomy. *Annals of Thoracic Surgery* 2003;76:407-12

Charalambos CP, Zipitis CS, Keenan DJ: Chest reexploration in the intensive care unit after cardiac surgery: a safe alternative to returning to the operative theater. *Annals of Thoracic Surgery* 2006;81:191-4.

Cheng, D: Randomized assessment of resource use in fast-track cardiac surgery 1-Year after hospital discharge. *Anesthesiology* 2003; Mar; 98(3); 651.

Consorta: Best Practice Models, Implementing CABG Best Practices. 2001. Available at:
http://www.consorta.com/wings/depts/oe/best_prac/

Cox JE: Transthoracic needle aspiration biopsy: variables that affect risk of pneumothorax. *Radiology* 1999;212(1):165-168.

Crocker HL, Ruffin RE: Patient-induced complications of a Heimlich flutter valve. *Chest* 1998;113(3), 838-839.

Cunnington J: Spontaneous pneumothorax. *Clinical Evidence* 2003;10:1738-1746.

Currie GP, Kennedy A, Paterson E, Watt SJ: A chronic pneumothorax and fitness to fly. *Thorax* 2007;62:187-189.

Daganou M, Dimopoulou I, Michalopoulos N, et al.: Respiratory complications after coronary artery bypass surgery with unilateral or bilateral internal mammary artery grafting. *Chest* 1998;113(5):1285-1289.

Davies CWH, Gleeson FV, Davies RJO: BTS guidelines for the management of pleural infection. *Thorax* 2003;58(Suppl II):ii18-ii28.

Drazen JM, Epstein AM: Guidance concerning surgery for emphysema. Editorial. *NEJM* 2003;348:2134-2136.

Droghetti A, Schiavini A, Muriana P, et.al.: Autologous blood patch in persistent air leaks after pulmonary resection. *Journal of Thoracic and Cardiovascular Surgery* 2006;132:556-559.

Fox V, Gould D, Davies N, Owen S: Patients' experiences of having an underwater seal chest drain: a replication study. *Journal of Clinical Nursing* 1999;8:684-692.

Freisner SA, Curry DM, Moddeman GR: Comparison of two pain-management strategies during chest tube removal: relaxation exercise with opioids and opioids alone. *Heart & Lung* 2006;35:269-276.

Golden P: Follow-up chest radiographs after traumatic pneumothorax or hemothorax in the outpatient setting: a retrospective review. *International Journal of Trauma Nursing* 1999;5(3):88-94.

Gordon P, Norton JM: Managing chest tubes: what is based on research and what is not? *Dimensions of Critical Care Nursing* 1995;14(1):14-16.

Gordon P, Norton JM, Merrel R: Refining chest tube management: analysis of the state of practice. *Dimensions of Critical Care Nursing* 1995;14(1):6-13.

Gordon PA, Norton JM, et al.: Positioning of chest tubes: effects on pressure and drainage. *American Journal of Critical Care* 1997;6(1):33-38.

Gray DT, Veenstra DL: Comparative economic analyses of minimally invasive direct coronary artery bypass surgery. *Journal of Thoracic and Cardiovascular Surgery* 2003;125:618-624.

Hagl C, Harringer W, Gohrbandt B, Haverich A: Site of pleural drain insertion and early postoperative pulmonary function following coronary artery bypass grafting with internal mammary artery. *Chest* 1999;115(3):757-761.

Hayes DD: Stemming the tide of pleural effusions. *Nursing Management* 2001;32(12):30-34.

Hazelrigg SR, Cetindag IB, Fullerton J: Acute and chronic pain syndromes after thoracic surgery. *Surgical Clinics of North America* 2002;82(4):849-865.

Heimlich HJ: Heimlich valve for chest drainage. *Medical Instrumentation* 1983;17(1):29-31.

Heimlich HJ: Valve drainage of the pleural cavity. *Diseases of the Chest* 1968;53(3):282-287.

Henry M, Arnold T, Harvey J: BTS guidelines for the management of spontaneous pneumothorax. *Thorax* 2003;58(Suppl II):ii39-ii52.

Houston S, Jesurum J: The quick relaxation technique: effect on pain associated with chest tube removal. *Applied Nursing Research* 1999;12(4):196-205.

Huber-Wagner S, Korner M, Ehrt A, Kay MV, Pfeifer K, Mutschler W, Kanz K: Emergency chest tube placement in trauma care – which approach is preferable? *Resuscitation* 2007;72:226-233.

Irwin JP, O-Yurvati A, Peska D: Rapid ambulation post-thoracotomy with the Atrium Express Mini-500 system. Available online at: <http://www.atriummed.com/PDF/RapidAmbulation.pdf>

Jones PM, Hewer RD, Wofenden HD, Thomas PS: Subcutaneous emphysema associated with chest tube drainage. *Respirology* 2001;6:87-89.

Kaczala GW, Skippen PW: Air medical evacuation in patients with airleak syndromes. *Air Medical Journal* 2008;27(2):91-98.

Kam AC, O'Brien M, Kam PCA: Pleural drainage systems. *Anaesthesia* 1993;48:154-161.

Kirkwood P: Ask the experts: chest tube care and transport. *Critical Care Nurse* 2002;22(4):70-72.

Kirkwood P: Ask the experts: removing chest tubes and suction bubbling. *Critical Care Nurse* 2000;20(3):97-98.

Ko JP: Factors influencing pneumothorax rate at lung biopsy: are dwell time and angle of pleural puncture contributing factors? *Radiology* 2001; 218(2), 491-496.

Krishnan JA: High-frequency ventilation for acute lung injury and ARDS. *Chest* 2000;118(3):795-807.

Landay M, Oliver Q, Estera A, Friese R, Boonswang N, DiMaio JM: Lung penetration by thoracostomy tubes: imaging findings on CT. *Journal of Thoracic Imaging* 2006;21(3):197-204.

Lang-Lazdunski L, Coonar AS: A prospective study of autologous 'blood patch' pleurodesis for persistent air leak after pulmonary resection. *European Journal of Cardiothoracic Surgery* 2004;26(5):897-900.

Lazar HL, Fitzgerald CA, Ahmad T, Bao Y, Colton T, Shapira OM, et al.: Early discharge after coronary artery bypass graft surgery: are patients really going home earlier? *Journal of Thoracic and Cardiovascular Surgery* 2001;121(5):943-950.

Laws D, Neville E, Duffy K: BTS guidelines for the insertion of a chest drain. *Thorax* 2003;58(Suppl II):ii53-ii59.

Leavitt BJ, O'Connor GT, Olmstead EM, et al.: Use of the internal mammary artery graft and in-hospital mortality and other adverse outcomes associated with coronary artery bypass surgery. *Circulation* 2001;103:507-512.

Leonard M: A 21-year-old man with pneumothorax, subcutaneous emphysema, and a persistent air leak after chest tube insertion. *Journal of Emergency Nursing* 2003;29:5:425-426.

Lichtenstein DA, Meziere G, Lascols N, et al: Ultrasound diagnosis of occult pneumothorax. *Critical Care Medicine* 2005;33(6):1231-1238.

Lim K, Tai S, Chan C, Hsu Y, Hsu W, Lin B, Lee K: Diagnosis of malpositioned chest tubes after emergency tube thoracostomy: is computed tomography more accurate than chest radiograph? *Journal of Clinical Imaging* 2005;29:401-405.

Linden PA, Bueno R, Colson YL, et al: Lung resection in patients with preoperative FEV1 < 35% predicted. *Chest* 2005;127(6):1984-1990.

Lois M, Noppen M: Bronchopleural fistulas: an overview of the problem with special focus on endoscopic management. *Chest* 2005;128:3955-3965.

Luchette FA, Barrie PS, Oswanski MF et al.: Practice management guidelines for prophylactic antibiotic use in tube thoracostomy for traumatic hemopneumothorax: the EAST practice management guidelines work group. *Journal of Trauma, Injury, Infection & Critical Care* 2000;48(4):753-757.

Marshall MB, Deeb ME et al: Suction vs water seal after pulmonary resection: a randomized prospective study. *Chest* 2002;121(3):831-835.

Martino K, Merrit S, Boyakye K et al.: Prospective randomized trial of thoracostomy removal algorithms including commentary with author response. *Journal of Trauma, Injury, Infection and Critical Care* 1999;46(3):369-373.

Maskell NA, Butland RJA: BTS guidelines for the investigation of a unilateral pleural effusion in adults. *Thorax* 2003;58(Suppl II):ii8-ii17.

Mimnaugh L, Winegar M, Mabrey Y, Davis, JE: Sensations experienced during removal of tubes in postoperative patients. *Applied Nursing Research* 1999;12(2):78-85.

National Emphysema Treatment Trial Research Group. A randomized trial comparing lung-volume-reduction surgery with medical therapy for severe emphysema. *NEJM* 2003;348:2059-2073.

National Emphysema Treatment Trial Research Group. Cost effectiveness of lung-volume-reduction surgery for patients with severe emphysema. *NEJM*; 2003;348:2092-2102.

National Emphysema Treatment Trial Research Group. Rationale and design of the National Emphysema Treatment Trial: a prospective randomized trial of lung volume reduction surgery. *Chest* 1999;116:1750-1761.

Obney J, Barnes MJ, Lisagor PG, Cohen DJ: Is bigger better for draining the mediastinum and thorax? [abstract] *Chest* 2000;118(4):116S.

Owen S, Gould D: Underwater seal chest drains: the patient's perspective. *Journal of Clinical Nursing* 1997;6(3):215-225.

Pacanowski JP, Waack ML, Daley BJ: Is routine roentgenography needed after closed tube thoracostomy removal? *Journal of Trauma, Injury, Infection & Critical Care* 2000;48(4):684-688.

Powner DJ: A review of "chest tubes" during donor care and after transplantation. *Progress in Transplantation* 2002;12:61-67.

Powner DJ, Cline CD, Rodman GH: Effect of chest-tube suction on gas flow through a bronchopleural fistula. *Critical Care Medicine* 1985;13(2):99-101. [classic for discussion of physics]

Proehl JA: One-way valve. In: JA Proehl (Ed.), *Emergency nursing procedures*. WB Saunders Company Philadelphia 1999. pp.137-139.

Puskas JD, Williams WH, Duke PG, et al. Off pump coronary artery bypass grafting provides complete revascularization with reduced myocardial injury, transfusion requirements, and length of stay: A prospective, randomized comparison of two hundred unselected patients undergoing off-pump versus conventional coronary artery bypass grafting. *Journal of Thoracic and Cardiovascular Surgery* 2003;125:797-808.

Putnam, JB: Malignant pleural effusions. *Surgical Clinics of North America* 2002;82(4):867.

Remerand F, Luce V, Badachi Y, Lu Q, Bouhemad B, Rouby J: Incidence of chest tube malposition in the critically ill. *Anesthesiology* 2007;106:1112-1119.

Roch A, Bojan M, Michelet P, et al: Usefulness of ultrasonography in predicting pleural effusions > 500ml in patients receiving mechanical ventilation. *Chest* 2005;127(1):224-232.

- Roman M, Weinstein A, Macaluso S: Primary spontaneous pneumothorax. *MedSurg Nursing* 2003;12(3):161-16.
- Rusch VW, Capps JS, Tyler ML, Pierson DL: The performance of four pleural drainage systems in an animal model of bronchopleural fistula. *Chest* 1988;93:859-863. [classic for discussion of physics]
- Russo L, Wiechmann RJ, Magovern JA et al.: Early chest tube removal after video-assisted thoracoscopic wedge resection of the lung. *Annals of Thoracic Surgery* 1998;66:1751-1754
- Sahn SA: Malignant pleural effusions. *Seminars in Respiratory and Critical Care Medicine* 2001;22(6):607-615.
- Saji H, Nakamura H, Tsuchida T et al.: The incidence and the risk of pneumothorax and chest tube placement after percutaneous CT-guided lung biopsy. *Chest* 2002;121(5):1521-1526.
- Sandrick K: Fast tracking surgical management improves patient outcomes and reduced hospital length of stay. *American College of Surgeons* 1999. Available online at: <http://www.meds.com/conrad/acs/fasttrack.html>
- Schlenker, EH: Cardiopulmonary anatomy and physiology. In: Hess, DR, MacIntyre, NR, Mishoe, SC, Galvin, WF, Adams, AB, Saposnick, AB (Eds.), *Respiratory care principles and practice*. WB Saunders Company Philadelphia 2002. pp.284.
- Schmelz JO, Johnson D, Norton JM, Andrews M, Gordon PA: Effects of position of chest drainage tube on volume drained and pressure. *American Journal of Critical Care* 1999;8(5):319-323.
- Schmidt U, Stalp M, Gerich T et al.: Chest tube decompression of blunt chest injuries by physicians in the field: effectiveness and complications. *Journal of Trauma, Injury, Infection & Critical Care* 1998;44(1):98-100.
- Shackcloth MJ, Poullis M, Jackson M, et.al.: Intrapleural instillation of autologous blood in the treatment of prolonged air leak after lobectomy: a prospective randomized controlled trial. *Annals of Thoracic Surgery* 2006;82:1052-1056.
- Sittig SE: Ventilation for life. *AARCTimes* 2002;26(1):18,20-21.
- Stafford RE, Linn J, Washington L: Incidence and management of occult hemothoraces. *American Journal of Surgery* 2006;192:722-726.
- Swain F, Martinez F, Gripp M, Razdan R, Gagliardi J: Traumatic complications from placement of thoracic catheters and tubes. *Emergency Radiology* 2005;12:11-18.
- Tang A, Hooper T, Hasan R: A regional survey of chest drains: evidence-based practice. *Postgraduate Medical Journal* 1999;75:471-474.
- Tang ATM, Velissaris TJ, Weeden DF: An evidence-based approach to drainage of the pleural cavity: evaluation of best practice. *Journal of Evaluation in Clinical Practice* 2002;8(3):333-340.

- Tattersall DJ, Traill ZC, Gleeson FV: Chest drains: does size matter? *Clinical Radiology* 2000;55:415-421.
- Vricella LA, Trachiotis GD: Heimlich valve in the management of pneumothorax in patients with advanced AIDS. *Chest* 2001;120(1):15-18.
- Wakai A, O'Sullivan RG, McCabe G: Simple aspiration versus intercostal tube drainage for primary spontaneous pneumothorax in adults. *Cochrane Database of Systematic Reviews* 2007, Issue 1 Art. No.:CD004479. DOI: 10.1002/14651858.CD004479.pub2.
- Walker KJ, Millar IL, Fock A: The performance and safety of a pleural drainage unit under hyperbaric conditions. *Anaesthesia and Intensive Care* 2006; 43:61-67.
- Wallen MM, Morrison AL, Gillies D, O'Riordan E, Bridge C, Stoddart F: Mediastinal chest drain clearance for cardiac surgery. *Cochrane Database of Systematic Reviews* 2007, Issue 2 Art. No.:CD003042. DOI: 10.1002/14651858.CD003042.pub2.
- Ware JH: The national emphysema treatment trial - how strong is the evidence? *NEJM* 2003;348:2055-2056.
- Weissberg D: Pneumothorax: Experience with 1,199 patients. *Chest* 2000;117:1279-1285.
- White PF, Rawal S, Latham P, et al.: Use of continuous local anesthetic infusion for pain management after median sternotomy. *Anesthesiology* 2003; 99(4): 918-923.
- Williams P, Laing R: Tension pneumothorax complicating autologous "blood patch" pleurodesis. *Thorax* 2005;60A:1066-1067.
- Yamagami T, Nakamura T, Iida S, Kato T, Nishimura T: Management of pneumothorax after percutaneous CT-guided lung biopsy. *Chest* 2002;121:1159-1164.

Classic References

- Capps JS, Tyler ML, Rusch VW, Pierson DJ: Potential of chest drainage units to evacuate broncho-pleural air leaks. *Chest* 1985;88S:57S. [classic for discussion of physics]
- Carroll PL: The principles of vacuum and its use in the hospital environment. 1995. Ohmeda, Inc.; Columbia, MD. [classic for discussion of physics]
- Duncan C, Erickson R: Pressures associated with chest tube stripping. *Heart & Lung* 1992;11(2):166-171. [classic on chest tube manipulation]

Duncan CR, Erickson RS, Weigel RM: Effect of chest tube management on drainage after cardiac surgery. *Heart & Lung* 1987;16(1):1-9. [classic on chest tube manipulation]

Gift AG, Bolgiano CS, Cunningham J: Sensations during chest tube removal. *Heart & Lung* 1991;20(2):131-137. [classic on chest tube removal]

Gordon P, Norton JM: Managing chest tubes: what is based on research and what is not? *Dimensions of Critical Care Nursing* 1995;14(1):14-16. [early evidence-based practice]

Gordon P, Norton JM, Merrel R: Refining chest tube management: analysis of the state of practice. *Dimensions of Critical Care Nursing* 1995;14(1):6-13. [early evidence-based practice]

Heimlich HJ: Valve drainage of the pleural cavity. *Diseases of the Chest* 1968;53(3):282-287. [first mention of Heimlich valve in the literature by its inventor]

Kam AC, O'Brien M, Kam PCA: Pleural drainage systems. *Anaesthesia* 1993;48:154-161. [classic for discussion of physics]

Powner DJ, Cline CD, Rodman GH: Effect of chest-tube suction on gas flow through a bronchopleural fistula. *Critical Care Medicine* 1985;13(2):99-101. [classic for discussion of physics]

Rusch VW, Capps JS, Tyler ML, Pierson DL: The performance of four pleural drainage systems in an animal model of bronchopleural fistula. *Chest* 1988;93:859-863. [classic for discussion of physics and gas flow]

Suggested Readings Regarding Chest Tube Stripping

Duncan C, Erickson R: Pressures associated with chest tube stripping. *Heart & Lung* 1992;11(2):166-171.

Duncan CR, Erickson RS, Weigel RM: Effect of chest tube management on drainage after cardiac surgery. *Heart & Lung* 1987;16(1):1-9.

Gordon P, Norton JM: Managing chest tubes: what is based on research and what is not? *Dimensions of Critical Care Nursing* 1995;14(1):14-16.

Gordon P, Norton JM, Merrel R: Refining chest tube management: analysis of the state of practice. *Dimensions of Critical Care Nursing* 1995;14(1):6-13.

Gross, SB: Current challenges, concepts and controversies in chest tube management. *AACN Clinical Issues in Critical Care* 1993;4(2):260-275.

Isaacson JJ, George LT, Brewer MJ: The effect of chest tube manipulation on mediastinal drainage. *Heart & Lung* 1986;15(6):601-605.

Lim-Levy F, Babler SA, DeGroot-Kosolcharoen J et al.: Is milking and stripping chest tubes really necessary? *Annals of Thoracic Surgery* 1986;42(1):77-80.

Oakes LL, Hinds P, Rao B et al.: Chest tube stripping in pediatric oncology patients: an experimental study. *American Journal of Critical Care* 1993;2(4):293-301.

Pierce JD, Naftel DC: Effects of two chest tube clearance protocols on drainage in patients after myocardial revascularization surgery. *Heart & Lung* 1991;20(2):125-130.

Teplitz L: Update: Are milking and stripping chest tubes really necessary? *Focus on Critical Care* 1991;18(6):506-511.